Minimally Invasive Surgery: Laparoscopy and Thoracoscopy

Manuel Jiménez Peláez, DVM, MRCVS, Diplomate ECVS

Davies Veterinary Specialists, Higham Gobion, Hertfordshire, UK

mjp@vetspecialists.co.uk

Minimally invasive surgery (MIS) allows diagnostic and/or therapeutic surgical procedures to be performed using very small incisions through which a camera and instruments are placed inside body cavities. We can visualise a magnified high quality image of the interior of these body cavities and joints using a highresolution monitor. Video-assisted surgery (VAS) is a surgical modality half-way between open conventional surgery and MIS, which combines the magnification and better visualisation offered by using the camera system, but uses larger incisions than in true MIS to facilitate the surgery, but smaller incisions than in conventional open surgery.

In humans, the development of minimally invasive surgery (MIS) has revolutionised surgery over the past 25 years. A large number of “open” conventional surgeries can now be performed using a minimal approach, which has application in several disciplines. MIS is widely used for diagnosis and treatment for abdominal (laparoscopic) and thoracic (thoracoscopic) procedures.

In veterinary medicine we are now able to offer pets many of the advantages of MIS and VAS that exist today in human medicine. Compared with traditional open surgery, MIS/VAS offers several advantages including decreased pain, better visualisation (due to the magnified high-resolution images produced), reduced risk of dehiscence and postoperative wound complications, as well as shorter hospitalisation times. In older and debilitated animals MIS is also likely to reduce other post-surgical complications. The benefits for the patients are often reinforced for the owner when they are able to see a much smaller surgical wound and scar compared to the larger incisions and scars produced by open surgery.

Although not all procedures can be performed using laparoscopic or thoracoscopic techniques, the list of operations that we can perform in this way is continuously growing.

Laparoscopy:

This technique allows exploration of the abdominal structures using small portals (between 5-12 mm); diagnostics and treatment can be offered for a large number of abdominal pathologies.

Procedures that can be performed using laparoscopy or video-assisted laparoscopy:

1. Exploratory laparoscopy and biopsies: Gastrointestinal tract, liver, spleen, pancreas, kidney, prostate, lymph nodes, abdominal masses in dogs and cats.
2. Ovariectomy/ovariohysterectomy in dogs. For routine sterilisation (spay) or reproductive tract neoplasia or ovarian remnant syndrome.
3. Uterus colpopexy and bladder colposuspension in dogs - for treatment of urinary incontinence in spayed female dogs (intrinsic sphincter dysfunction) and as treatment of “intra-pelvic bladder”.
4. Cryptorchidectomy in dogs/cats - removal of retained abdominal testicle(s).
5. Cystotomy in dogs/cats - for removal of bladder stones or biopsy of bladder cancer.
6. Gastropexy in dogs - for preventative treatment of gastric dilation and volvulus syndrome (large and giant breed dogs, especially Great Danes).
7. Colopexy and cystopexy in dogs - part of the treatment for perineal hernia (abdominal surgical time before herniorrhaphy time)
8. Ureteronephrectomy - removal of the kidney and ureter for chronic pyelonephritis/ abcess, neoplasia, dysplasia of the kidney.
9. Adrenalectomy - removal of the adrenal gland for modestly sized adrenal cortical tumour/pheochromocytoma (not invading the caudal vena cava) or incidentally discovered adrenal masses (incidentalomas).
10. Liver lobe resection/partial resection - for liver biopsy or modestly-sized peripherally located liver tumour resection.
11. Insulinoma Resection - partial pancreatectomy for insulinoma removal.
12. Cholecystectomy - gall bladder removal in case of unruptured gall bladder without bile peritonitis. Primarily for stable dogs with biliary mucocele or gall stone disease.

Thoracoscopy :

The following is a list of the procedures that can be performed using thoracoscopy or video-assisted thoracoscopy:

1. Exploratory thoracoscopy and biopsies - biopsies can be obtained from pleura, lymph nodes, masses etc.
2. Partial or subtotal pericardectomy - removal of the pericardium for palliation of idiopathic or cancer-associated bleeding into the pericardial sac, pericardial biopsy or as an adjunct to treatment of idiopathic chylothorax.
3. Lung biopsy, lung lobe removal - for neoplastic/inflammatory lung conditions. Lung lobectomy is possible for modestly sized peripherally located primary lung tumours, abscess or for single metastatic lesions. Some cases of spontaneous pneumothorax (bullous emphysema) may also be treated by partial or complete lung lobectomy.
4. Cranial mediastinal mass biopsy or mass resection for thymoma removal when tumour is not large or invasive. Other masses can be biopsied under thoracoscopic guidance.
5. Thoracic duct ligation - for management of idiopathic chylothorax.
6. Persistent right aortic arch (PRAA) and retention of left ligamentum arteriosum – for treatment of esophageal constriction caused by the ligamentum arteriosum traversing from the right aortic arch to the main pulmonary artery.
7. Occlusion of a patent ductus arteriosus (PDA) using titanium ligating clips or ligatures.

THROUGH THE KEYHOLE: LAPAROSCOPIC ADRENALECTOMY IN DOGS

Manuel Jiménez Peláez, DVM, MRCVS, Diplomate ECVS
Davies Veterinary Specialists, Higham Gobion, Hertfordshire, UK
mjp@vetspecialists.co.uk

Key Points

- Adrenalectomy can readily be performed using laparoscopy; however, promt conversion to an open approach may be required and equipment required should be available and ready on the surgical table.

- Laparoscopic adrenalectomy in dogs is usually performed via a paralumbar fossa, or flank approach. An initial abdominal exploration may, however, be carried out through a port on the ventral midline, using gravity as an aid.

- Laparoscopic adrenalectomy is feasible in dogs for right and left adrenal tumors which do not invade the caudal vena cava; however, given the different anatomic relationships, right-sided adrenal tumors are particularly challenging to remove. Vascular invasion is a clear contraindication to laparoscopic removal; contrast CT may increase the ability to diagnose vascular invasion prior to laparoscopic exploration.

- Using an advanced tissue and vessel-sealing device is of a paramount importance improving safety and reducing surgical time. Such a device can be used for both haemostasis of the phrenico-abdominal vein and dissection of the gland.

- Good case selection, experience and availability of high-quality equipment are critical to avoid high levels of procedural complications and conversion rates.

Surgical Technique:

The caudal aspect of the hemithorax and the lateral abdomen on the affected side are clipped and prepared aseptically for surgery. Dogs are positioned in lateral recumbency on the unaffected side, with a cushion placed under the erector spinae muscle group to raise the spine towards the surgeons who are positioned at the animal's ventral aspect (Fig 1).

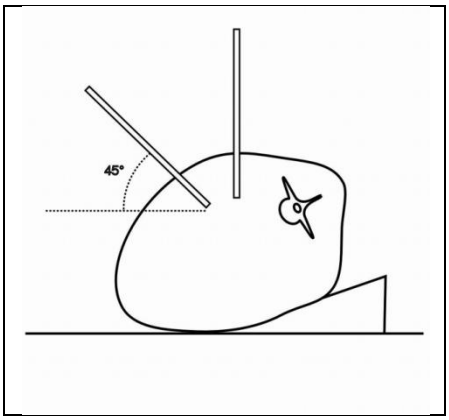

Fig 1. Schematic representation of the dog's surgical position (lateral recumbency) and orientation of the portals. A triangular cushion was placed under the erector spinae muscle group in order to raise the spine towards the surgeons standing by the animal's ventral side.

The video monitor is positioned in front of the surgeons on the dorsal side of the dog. A 5- or 10-mm (30° or 0°) laparoscope is connected to a video camera and a light source. Images are viewed on a video monitor and recorded. The endoscopic equipment includes an irrigation–suction unit, a self-retaining fan retractor, grasping forceps, scissors and dissectors connected to an electrosurgical unit, as well as endoscopic hemoclips. Most importantly, a feedback-controlled, bipolar vessel-sealing system device is used to achieve hemostasis of the phrenico-abdominal vein and dissection of the gland.

Although adrenalectomy in dogs is usually done via a paralumbar fossa (flank) approach, an initial abdominal exploration may be made with a port on the ventral midline, using gravity to evaluate the dorsal, cranial, and caudal aspects of the abdomen. This retro-umbilical port is not a very useful position for the endoscope during adrenalectomy and does not improve the view, and manipulation becomes difficult. Once the abdominal exploration has been completed, the patient is re-positioned in almost lateral recumbency for the adrenalectomy. A Veress needle was inserted at a level just caudal to the 13th rib in the paralumbar fossa ipsilateral to the affected side. The abdomen is inflated with CO_2 until an intra-abdominal pressure of 8–10mm Hg is achieved. Inflation is adjusted according to the dog's size and physiologic variables.

Four portals are located in the paralumbar fossa. Three 5-mm portals are placed along a virtual half-circle with kidney of the affected side as the center point. A fourth instrumental portal (5–12mm) for the self-retaining fan retractor and suction device is located above the kidney. The half-circle radius is determined subjectively, according to dog and instrument size (Fig 2).

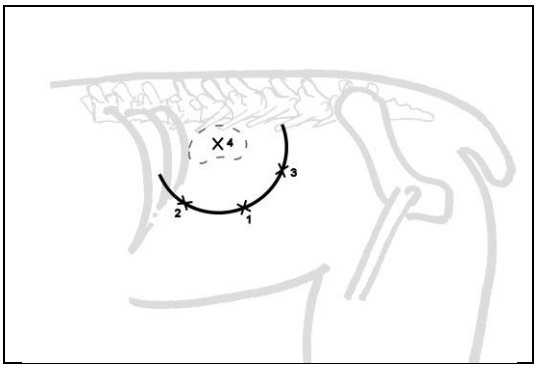

Fig 2. Positions of the surgical portals along the paralumbar fossa.

The surgeon should triangulate ports toward the affected adrenal gland. The laparoscope is inserted through portal 1 and the instruments through portals 2 and 3. Laparoscope and instruments can be exchanged alternatively from one portal to another to improve visualization and dissection.

Exposure and dissection of the adrenal glands are performed differently on the right and left sides because of anatomic differences:

- Right adrenalectomy:

To achieve wide exposure of the right adrenal gland, the right lateral hepatic lobe is retracted cranially and the kidney was retracted dorsally. Because dogs are positioned in lateral recumbency with a cushion under the erector spinae muscle group (Fig 1), the descending duodenum or other organs are displaced by gravity.

- Left adrenalectomy:

For exposure of the left adrenal gland, the descending colon is reflected medially, the left kidney is reflected dorsally, and the spleen ventrally.

Immediately after exposure of the adrenal gland, evaluate the phrenicoabdominal vein, renal vein, and caudal vena cava (CVC) in each case. Then careful dissection and hemostasis of the phrenicoabdominal vein is achieved on both sides by the use of either haemostatic endoclips or a vessel-sealing device. Dissection between the right adrenal gland and the caudal vena cava has to be to be performed with special care.

In an attempt to minimize manipulation of the adrenal gland, the peritoneum is incised laterally away from the adrenal gland. Any direct manipulation or grasping of the adrenal capsule must be avoided as inadvertent capsule penetration is likely to happen. The vessel-sealing device helps to perform a complete circumferential dissection of the gland with minimal manipulation of the gland itself. The renal blood supply is retracted medially to avoid accidental hemorrhage during dissection. Further hemostasis of vessels

on the caudal and cranial parts of the gland is also achieved using the vessel-sealing device. The gland should be removed using an endoscopic retrieval bag.
The abdomen is inspected for hemorrhage, and the adrenalectomy site is lavaged.
The abdomen is freed of gas and closure of the portal wounds is performed in a routine manner.

Discussion:

Currently, adrenalectomy is the treatment of choice for adrenal tumors, unless metastatic lesions are encountered preoperatively. Some of the more common techniques used for open adrenalectomy in dogs include ventral median celiotomy and retrocostal or flank laparotomy. Selection of approach is based on adrenal gland size, surgeon's preference, affected side, and presence of neoplastic invasion of the caudal vena cava. Pros and cons of various approaches have been reported. A retroperitoneal approach via flank incision is usually recommended for small lesions within the right adrenal gland in the absence of invasion of the caudal vena cava. The left adrenal gland can be exposed without much difficulty by flank or ventral median approaches. The latter approach is recommended for large tumors, pheochromocytomas, or tumors extending in the caudal vena cava, regardless of lateralization.

Laparoscopic adrenalectomy in humans was reported in 1992 and is most commonly used, but not exclusively, for benign functional and nonfunctional tumors (< 12cm in size) of the adrenal glands; however, the true upper limit may not have been reached with the advent of morcellators. The benefits of laparoscopic adrenalectomy are well documented in people and include fewer wound complications, reduced morbidity, improved comfort and cosmetic appeal, reduced bleeding, better observation of abdominal organs, shorter hospital stays, and faster recovery periods.

Advantages of minimally invasive surgical procedures in dogs compared with open surgical procedures have been reported. For example laparoscopic ovariohysterectomy reduces postoperative pain and surgical stress compared with the open technique. Furthermore one can expect that laparoscopic adrenalectomy would offer the advantages of minimally invasive procedures which include limited manipulation of others abdominal organs, decreased surgical wound complication, improved postoperative comfort, shorter recovery periods and excellent view of abdominal structures. This magnification is especially helpful during dissection between the right adrenal gland and caudal vena cava.

Inadvertent opening of the capsule (suctioning of the contents and removal of the remainder) was not problematic in the case series we previously reported. Problems associated with capsular rupture are unknown, no apparent complications occurred, but a larger study would be required to evaluate the effect on survival. Capsular rupture observed in these first few cases is likely due to a combination of the learning curve and the absence of a vessel-sealing device. Capsule rupture is more likely to occur during right adrenalectomy given its anatomic position.

Trans-abdominal or retro- peritoneal approaches have been described but the lateral trans-abdominal approach is the most commonly used technique in human laparoscopic adrenalectomy because the large view provides good orientation and visualization of familiar landmarks known from open surgery. The retroperitoneal approach provides a more direct access to the adrenal gland and avoids abdominal adhesions in patients who have had previous abdominal surgery. However, dissection and exposure are more difficult, the working space is limited, and this approach does not permit full abdominal exploration. For these reasons as well as body size the trans-abdominal laparoscopic approach is also preferred in dogs. As in human beings our patients are placed in lateral recumbency on the unaffected side, with a cushion placed under the erector spinae muscles to rise the spine towards the surgeons who were standing on the ventral side of the animal. The surgical portals are placed at different levels along the paralumbar fossa using a trans-peritoneal approach (Fig. 2). This allows excellent exposure of the adrenal gland and very good view during its dissection, especially between right adrenal gland and the caudal vena cava.

Dissection distant from the adrenal gland without entering it or disrupting the CVC must be accomplished. It is especially difficult and challenging during dissection between the right adrenal gland and the CVC because the right adrenal gland is extremely close to the CVC and on its medial aspect the capsule is continuous with the tunica adventitia of the CVC. Dissection of the phrenico-abdominal vein must be carefully performed to avoid bleeding and gland effraction. Haemostasis of the right phrenico-abdominal vein is performed at its junction with the caudal vena cava. Because of left phrenico-abdominal vein enters the left renal vein and doesn't join directly with the CVC, its dissection is easier to perform. Bleeding is the most common complication during and after laparoscopic adrenalectomy in people, and accounts for approximately 40% of all complications. Nonetheless, blood transfusions are required in less than 5% of cases. In dogs, use of surgical devices as Harmonic Scalpel® or LigaSure® helps preventing bleeding efficiently.

In the series we published and other unpublished data from several authors, all dogs presented without CVC invasion were operated laparoscopically and no dog required conversion to open surgery. In dogs, laparoscopy was used with adrenal masses of no more than 48 mm in diameter. Conversion to an open procedure occurred in approximately 2% of human cases (ranged, 0-13%) and the main indication for conversion is uncontrollable bleeding (40% of all complications).The next most common reason for conversion is malignancy with local and vascular invasion detected upon laparoscopic exploration.

In people postoperative complications after laparoscopic adrenalectomy include bleeding, wound infection or hematoma, as well as thromboembolic, urinary, gastrointestinal, pulmonary, and cardiovascular problems. Injury to peritoneal and retroperitoneal organs represents only 5% of all complications and includes injury to the liver parenchyma, spleen, pancreas, colon, lymphatic system, and adrenal gland (specimen fragmentation). Minor splenic injury and controllable bleeding are the most often complications reported during laparoscopic procedures in dogs. Acute pancreatitis with peritonitis has been reported to be responsible of 8 to 25% of mortality after open adrenalectomy, especially with the ventral midline approach. In the reported case series, no pancreatitis has been observed. Further investigation is required in order to evaluate the role of the minimally

invasive surgical approach in this major difference. No iatrogenic injury was noted as a result of trocar insertion in the cases reported.

Causes of death after laparoscopic adrenalectomy in humans included massive hemorrhage, necrotizing pancreatitis, pulmonary embolism, sepsis, and cardiopulmonary failure. When compared with open adrenalectomy, laparoscopic approach reduces the likelihood of perioperative complications in human patients undergoing adrenalectomy. Positive impacts on intraoperative bleeding and postoperative pulmonary complications have been demonstrated. The overall mortality rate in people appears ranged of 0.2-1.2% after a period of 30 days post-procedure.
In the series we published the perioperative mortality rate for adrenocortical tumors was 28% (2/7 dogs, both in the postoperative period). Although this number is high it should be compared with reported mortality rate of 19 (4/21), 21% (6/28), 28% (10/36), and 60% (15/25) from other studies. Major postoperative complication included severe respiratory distress in 2 of 7 dogs, (both died 48 hours after surgery and none of which had a definitive diagnosis for the cause). Thoracic radiographs were compatible with pulmonary thromboembolism, which is a well known postoperative complication in animals and men suffering from hyperadrenocorticism. Dogs with hyperadrenocorticism that undergo surgery (e.g. adrenalectomy) are at increased risk of developing pulmonary thromboembolism. In humans beings, it has been shown that these thromboembolic complications may be reduced by peri-operative anticoagulation treatment. Although we do not routinely anticoagulate patients with Cushing's syndrome, it may be advisable to start preoperative low-dose heparin therapy and to continue administration for several days afterward, to help reduce the chances for embolic events. However, pulmonary thromboembolism has also been described in series of dogs treated with an anticoagulant protocol (heparin) during and after open adrenalectomy. At this moment, to our knowledge no studies have demonstrated the benefit of this treatment to prevent pulmonary thromboembolism in dogs. Further studies are also needed to establish if, in addition, intermittent positive pressure ventilation and pneumoperitoneum increase the likelihood of thromboembolism in Cushing patients, regardless of the type of surgical procedure. In people, laparoscopy induces specific pathophysiological changes in response to pneumoperitoneum which is felt to predispose to deep venous thrombosis. No studies are available confirming this in dogs. Information on the incidence of venous thromboembolism following laparoscopic procedures is insufficient to warrant the need for thromboprophylaxis. In addition, venous thromboembolism remains a common and severe complication after cancer surgery in people. It's the most common cause of death at 30 days after cancer surgery.
In our patients, the perioperative mortality of open surgery (22%) would not be expected to be any different with laparoscopic surgery, nor would the overall survival (690d).

Pheochromocytomas can be also removed laparoscopically. No major change in blood pressure of human patients with pheochromocytoma occurred when CO_2 insufflation was performed. Consideration to alpha/beta receptor blockade should be made; however, as would be done for open surgery, as laparoscopy will not minimize these complicating factors.

Laparoscopic surgery is presumably less painful because of smaller incisional size and decreased skin and muscular trauma. Although in any of the cases pain scores were evaluated, all dogs were standing up the day after surgery and palpation of the abdomen was not painful. Dogs were discharged 72 hours after surgery and no dogs required analgesic drugs at home. Wound complications (infections, delayed wound healing) are well known complications in animals with hyperadrenocorticism, so minimizing wound size can only be beneficial. Abdominal incision dehiscence has been reported in 10% of cases after open adrenalectomy. In the reported case series, despite some severe preexisting skin lesions, no wound complications other than mild cellulitis were observed.

Disadvantages or problems reported with laparoscopic adrenalectomy include, increased surgical time, the specific instrumentation required, technical difficulties and intraoperative complications during dissection (mild bleeding and gland rupture). As with any laparoscopic technique, laparoscopic adrenalectomy may be potentially longer to perform and more technically demanding than conventional techniques until familiarity allows full confidence. The reported mean surgical time for laparoscopic adrenalectomy in dogs, from Veress needle insertion to complete closure is 113 minutes (range 90-150 minutes). Because of different anatomic position, mean surgical time for right adrenal gland (133 minutes, range 120-150 minutes) was longer than mean surgical time for left adrenal gland (99 minutes, range 90-110 minutes). In some cases, surgical time with the open approach may be shorter to perform, but to our knowledge, this surgical time is only reported in a few studies and it varied from 100 to 180 minutes. Laparoscopic removal may take longer in people (258 vs 166 min), but certainly is related to surgeon experience, size of the tumor, body condition score, and ability to visualize the organ. As any minimally invasive procedure, it requires specific instrumentation which is more expensive. However use of reusable instruments can decrease instrumentation costs.

In human surgery, the role of laparoscopic adrenalectomy in the management of adrenocortical cancer is controversial because of its high morbidity. Most adrenocortical cancers are generally treated by open adrenalectomy. Relative contraindications to laparoscopic adrenalectomy include large tumors and suspected adrenocortical cancer. However, laparoscopic adrenalectomy appears to be safe and effective for malignant adrenal tumors in people (adrenocortical carcinoma and malignant pheochromocytoma) without local or vascular invasion confirmed and if the rules of oncologic surgery can be respected. Local and/or port-site tumor recurrence and intra-abdominal carcinomatosis from laparoscopic adrenalectomy for malignant adrenal tumors have been described in several reports. Other reports have described no local and no port-site recurrence after laparoscopic adrenalectomy for malignant tumors with negative margins in all cases. In patients with adrenocortical cancer, loco-regional recurrence rates were 60%, a rate similar to that reported for open adrenalectomy. Despite effraction of the gland capsule, no evidence of local or port site recurrence has been observed in the cases which have been reported.

Laparoscopic adrenalectomy is feasible in dogs for right and left adrenal tumors not involving the caudal vena cava. It offers the advantages of a mini-invasive surgery including decreased pain, better visualization, less risk of dehiscence and postoperative wound complications, and shortened hospitalization time and convalescence. Although promising, further studies are required in order to compare the short and long term results of laparoscopic adrenalectomy in dogs with the ventral midline or retro-costal open approaches.

References:

Jiménez Peláez M, Bouvy BM, Dupre GP: Laparoscopic adrenalectomy for treatment of unilateral adrenocortical carcinomas: Techniques, complications and results in seven dogs. *Vet Surg* 2008; 37:444.

Mayhew PD, Hunt GB, Steffey MS et al: Laparoscopic adrenalectomy for resection of adrenal neoplasms in eight dogs and one cat. Proceedings of the Veterinary Endoscopy Society Annual Meeting. Ambergris Caye, Belize: 2011, p. 14

Radlinsky M. Laparoscopic approach to adrenalectomies and pancreatic surgery. Proceedings of the ACVS Symposium Equine and Small Animal, Washington, Seattle, WA. October 21-23, 2010, p. 296-298.

Veterinary Surgery
37:444–453, 2008

Laparoscopic Adrenalectomy for Treatment of Unilateral Adrenocortical Carcinomas: Technique, Complications, and Results in Seven Dogs

MANUEL JIMÉNEZ PELÁEZ, DVM, MRCVS, BERNARD M. BOUVY, DVM, MS, Diplomate ECVS, Diplomate ACVS, and GILLES P. DUPRÉ, DVM, Diplomate ECVS

Objective—To investigate the feasibility of, and outcome after, laparoscopic adrenalectomy in dogs with unilateral adrenocortical carcinoma.
Study Design—Case series.
Animals—Dogs (n = 7) with Cushing's syndrome caused by unilateral adrenocortical carcinoma.
Methods—Laparoscopic adrenalectomy with the dog in lateral recumbency on the unaffected side. Three 5-mm portals (1 laparoscopic portal, 2 instrument portals) were placed in the paralumbar fossa. A fourth instrumental portal (5–12 mm) was placed above the kidney. After dissection and hemostatic control of the phrenicoabdominal vein, the adrenal gland was carefully dissected or when there was capsule fragility, necrotic content was partially aspirated. The remaining glandular tissue was removed through the 12-mm trocar site.
Results—Dogs with unilateral adrenocortical carcinoma (3 right-sided, 4 left-sided) without invasion of the caudal vena cava were successfully operated by laparoscopic approach. There were no significant intraoperative complications; 2 dogs died within 48 hours of surgery because of respiratory complications. Five dogs were discharged 72 hours after surgery, and signs of hyperadrenocorticism disappeared thereafter (survival time ranged from 7 to 25 months).
Conclusions—Laparoscopic adrenalectomy is feasible in dogs with either right- or left-sided adrenocortical carcinoma not involving the caudal vena cava.
Clinical Relevance—When performed by experienced surgeons, laparoscopic adrenalectomy offers a minimally invasive alternative to open laparotomy or retroperitoneal surgery for the treatment of unilateral adrenocortical carcinoma in dogs.

INTRODUCTION

SPONTANEOUS HYPERCORTISOLISM (Cushing's syndrome) is a common endocrinopathy in middle-aged to old dogs resulting from hyperadrenocorticism. In 80–85% of affected dogs, hypercortisolism is caused by excessive secretion of the adrenocorticotropic hormone (ACTH) by the pituitary gland, resulting in bilateral adrenal hyperplasia. Adrenocortical tumors account for the remaining 15–20% of cases of spontaneous hyperadrenocorticism in dogs. Bilateral adrenal tumors occur rarely in the dog, and are more frequently unilateral (adenomas in 40–50%; carcinomas in 50–60%).[1,2] Currently, adrenalectomy is the treatment of choice for adrenal tumors, unless metastatic lesions are encountered preoperatively.[1–3]

Some of the more common techniques used for open adrenalectomy in dogs include ventral median celiotomy

From the Centre Hospitalier Vétérinaire Frégis, Arcueil, France and the Veterinärmedizinische Universität Wien, Vienna, Austria.
Presented in part at the 15th Annual Scientific Meeting of the European College of Veterinary Surgeons, Sevilla, Spain, July 2006.
Address reprint requests to Manuel Jiménez Peláez, DVM, MRCVS, Soft Tissue Surgery Unit, Centre for Small Animal Studies, Animal Health Trust, Lanwades Park, Kentford, Newmarket, Suffolk CB8 7UU, UK. E-mail: dr_jimenez_pelaez@hotmail.com; Gilles.Dupre@vu-wien.ac.at.
Submitted July 2007; Accepted November 2007

0161-3499/08
doi:10.1111/j.1532-950X.2008.00410.x

and retrocostal or flank laparotomy.[3–8] Selection of approach is based on adrenal gland size, surgeon's preference, affected side, and presence of neoplastic invasion of the caudal vena cava. Pros and cons of various approaches have been reported.[4–9] A retroperitoneal approach via flank incision is usually recommended for small lesions within the right adrenal gland in the absence of invasion of the caudal vena cava. The left adrenal gland can be exposed without much difficulty by flank or ventral median approaches. The latter approach is recommended for large tumors, pheochromocytomas, or tumors extending in the caudal vena cava, regardless of lateralization.[4–10]

Laparoscopic adrenalectomy in humans was reported in 1992[11,12] and is most often used for benign functional and nonfunctional tumors (<12 cm in size) of the adrenal glands.[13–16] Laparoscopic adrenal surgery may offer several advantages including fewer wound complications, reduced morbidity, improved comfort and cosmetic appeal, reduced bleeding, better observation of abdominal organs, shorter hospital stays, and faster recovery periods.[14–34] Advantages of minimally invasive surgical procedures in dogs compared with open surgical procedures have been reported and laparoscopic ovariohysterectomy reduces postoperative pain and surgical stress compared with the open technique.[35–37]

Given the promising results in humans and well-known advantages of minimally invasive surgery in dogs, studying the feasibility and efficacy of laparoscopic adrenalectomy in dogs with unilateral adrenal tumors seemed warranted. We report our experience with 7 dogs and procedural details for minimally invasive laparoscopic adrenalectomy in dogs with unilateral adrenal tumors that have not invaded the caudal vena cava.

MATERIALS AND METHODS

Inclusion Criteria

Medical records (Centre Hospitalier Vétérinaire Frégis, November 2004–September 2005; Veterinärmedizinische Universität Wien, November 2005–July 2006) of dogs with Cushing's syndrome caused by unilateral adrenal tumor, referred for surgical treatment were reviewed. Dogs that had neoplastic invasion of the caudal vena cava were excluded. Recorded variables were age, body weight, breed, clinical signs, location and size of the affected adrenal gland, surgical time, complications, and clinical outcome.

Diagnostic Evaluation

Upon admission, clinical signs and endocrine tests (urine cortisol/creatinine ratio, ACTH stimulation, low- and high-dose dexamethasone tests) performed by the referring veterinarians were consistent with hyperadrenocorticism associated with adrenal gland tumors in dogs included in this report. Complete blood count (CBC), serum biochemical profile, thoracic radiographs and abdominal ultrasonography were performed in all dogs before surgery. One dog had an abdominal computed tomography (CT) scan.

Anesthesia

Dogs were premedicated with either morphine hydrochloride (0.1 mg/kg subcutaneously [SC]) and diazepam (0.2 mg/kg intravenously [IV]) at the Centre Hospitalier Vétérinaire Frégis, or methadone (0.1 mg/kg IV) and midazolam (0.2 mg/kg IV) at the Veterinärmedizinische Universität Wien. Anesthesia was induced with propofol (6 mg/kg IV) and maintained with isoflurane in 100% oxygen. Controlled ventilation was provided and ECG, noninvasive or invasive (Veterinärmedizinische Universität Wien) blood pressure, capnography and pulse oximetry were monitored. Dexamethasone (0.2 mg/kg IV) was administered immediately after anesthetic induction.

Surgical Technique

The caudal aspect of the hemithorax and the lateral abdomen on the affected side were clipped and prepared for aseptic surgery. Dogs were positioned in lateral recumbency on the unaffected side, with a cushion placed under the *erector spinae* muscle group to raise the spine towards the surgeons who stood against the animal's ventral side (Fig 1). The video monitor was positioned in front of the surgeons on the dorsal side of the dog.

A 5-mm, 30° or 0° laparoscope (Stryker Endoscopy, 93290 Tremblay, France or Karl Storz Endoskop, 1030 Wien) was connected to a video camera (Stryker Endoscopy or Karl Storz Endoskope) and a light source (Quantum 4000 Stryker Endoscopy or Xenon Nova 300 Karl Storz Endoskope). Images were viewed on a video monitor and recorded. The endoscopic equipment included an irrigation–suction unit

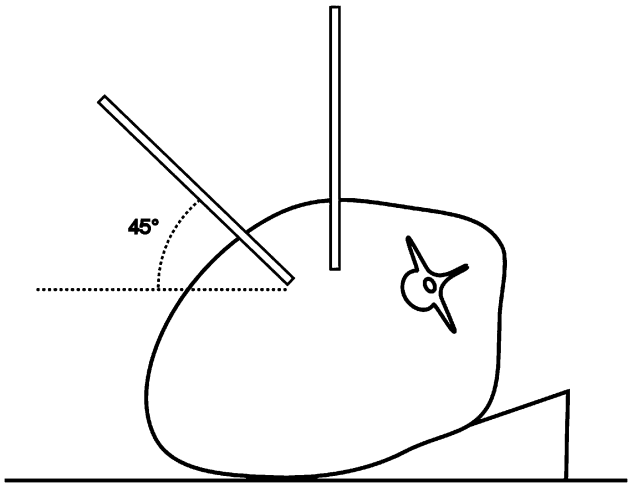

Fig 1. Schematic representation of the dog's surgical position (lateral recumbency) and orientation of the portals. A triangular cushion was placed under the *erector spinae* muscle group in order to raise the spine towards the surgeons standing by the animal's ventral side.

(SURGIWAND II, Tyco Healthcare, 78990 Elancourt, France), a self-retaining retractor (ENDO RETRACT II, Tyco Healthcare), bipolar forceps (BIPOLAR-ZANGEN 5 mm, Karl Storz Endoscope, 51100, Reims, France), grasping forceps (ENDO GRASP, Tyco Healthcare), scissors (ENDO SHEARS, Tyco Healthcare) and dissectors (ENDO DISSECT, Tyco Healthcare) connected to an electrosurgical unit, as well as endoclips (ENDO CLIP II ML, Tyco Healthcare). In 2 dogs, a LigaSure® device (LigaSure™ Lap, LigaSure Atlas™, Valleylab, Tyco Healthcare, 2345 Brunn am Gebirge, Austria), a feedback-controlled, bipolar vessel-sealing system used to achieve hemostasis was used.

After draping, a Verres needle was inserted at a level just caudal to the 13th rib in the paralumbar fossa ipsilateral to the affected side. The abdomen was inflated with CO_2 until an intra-abdominal pressure of 8–10 mm Hg was achieved. Inflation was adjusted according to the dog's size and physiologic variables.

Four portals were located in the paralumbar fossa. Three 5-mm portals were made along a virtual half-circle with kidney of the affected side as the center point. The half-circle radius was determined subjectively, according to dog and instrument size (Fig 2). The laparoscope was inserted through portal 1 and the instruments through portals 2 and 3. A fourth instrumental portal (5–12 mm) for the self-retaining retractor and suction device was located above the kidney.

Laparoscopic examination of tissues surrounding the affected adrenal gland and partial examination of the liver (incomplete because of the lateral position) was performed. Absence of liver macrometastases and macroscopic vascular invasion into the caudal vena cava was confirmed in all dogs.

Exposure and dissection of the adrenal glands were performed differently on the right and left sides because of anatomic differences.

Right Adrenalectomy. To achieve wide exposure of the right adrenal gland, the right lateral hepatic lobe was retracted cranially whereas the kidney was retracted dorsally. Because dogs were positioned in lateral recumbency with a cushion under the erector spinae muscle group (Fig 1), the descending duodenum or other organs were displaced by gravity. Dissection between the right adrenal gland and the caudal vena cava was carefully performed using an endoscopic dissector.

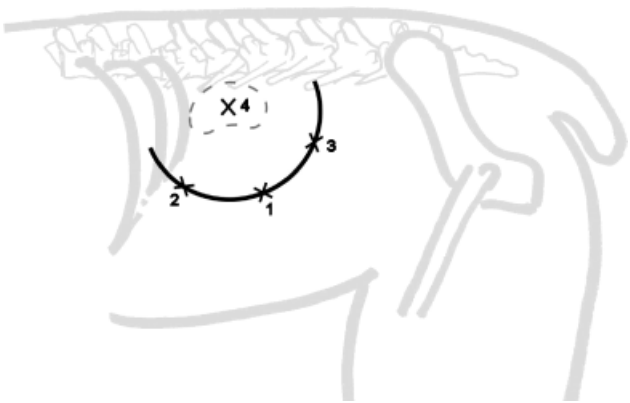

Fig 2. Positions of the surgical portals along the paralumbar fossa (no. 1 = laparoscope; nos. 2–4 = instruments).

Left Adrenalectomy. For exposure of the left adrenal gland, the descending colon was reflected medially, the left kidney was reflected dorsally, and the spleen ventrally.

Immediately after exposure of the adrenal gland, careful dissection and hemostasis of the phrenicoabdominal vein was achieved on both sides by the use of either bipolar electrocautery, haemostatic endoclips, or the LigaSure®. To minimize manipulation of the adrenal gland, the peritoneum was incised lateral to the adrenal gland (Fig 3). Additionally, the periadrenal tissue was grasped using a blunt grasper to facilitate complete circumferential dissection of the gland using either bipolar dissection or the LigaSure® device. The renal blood supply was retracted medially to avoid accidental hemorrhage during dissection. Further hemostasis of vessels on the caudal and cranial parts of the gland was achieved using bipolar electrocautery or the LigaSure® device.

When the gland was friable and under tension, or in the case of spontaneous rupture, a small window in the capsule was used to aspirate the necrotic semiliquid content at the center of the gland by using an irrigation–suction unit. After careful dissection, the remaining glandular tissue was progressively entirely removed in small pieces through the 12-mm protected trocar to prevent abdominal wall contamination. The abdomen was inspected for hemorrhage, and the adrenalectomy site was locally rinsed with small volumes of warmed lactated Ringer solution and concurrent use of close suction to avoid abdominal contamination with neoplastic cells. After abdominal deflation the laparoscopic portals were closed.

Excised adrenal tissue was submitted for pathologic examination.

Postoperative Care

Morphine hydrochloride (0.1 mg/kg SC) or buprenorphine hydrochloride (0.01 mg/kg IV) were administered for postoperative analgesia every 4–6 hours for 24–36 hours. Cefalexine

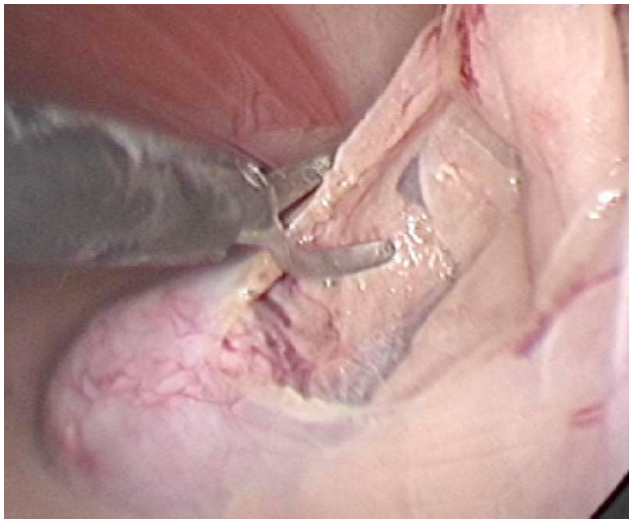

Fig 3. Laparoscopic intraoperative view: distant dissection of a left adrenal gland through the peritoneum.

(15 mg/kg orally every 12 hours) was administered for 5–10 days. IV fluids (0.9% NaCl) with dexamethasone (0.05 mg/kg IV every 6 hours) were administered during the first 24–36 hours. Desoxycorticosterone acetate (DOCA; 0.2 mg/kg intramuscularly [IM] once daily) was also administered until hospital discharge (3 days).

When dogs began eating and drinking, prednisolone (0.2 mg/kg orally every 12 hours) was used instead of dexamethasone. Dosage of prednisone was tapered (0.1 mg/kg orally) over 4–6 weeks, and then discontinued. One IM DOCA injection every 2–3 days was administered between the second and the fourth weeks. Rest and leash walk were recommended for 3 weeks after surgery. We recommended an ACTH stimulation test within 3 weeks after surgery.

Outcome

Dogs were re-evaluated either by the operating surgeons or by the referring veterinarian. All owners and referring veterinarians were contacted via telephone to obtain follow-up information.

RESULTS

Clinical Findings (Table 1)

Dogs had a mean age 11 years (range, 9–14 years) and weight of 19 kg (range, 7–37 kg). No pulmonary metastases were identified and ultrasonography (Table 1) or CT scan confirmed the presence of unilateral adrenal tumor not involving the caudal vena cava. Tumors were left-sided in 4 dogs and right-sided in 3 dogs. Mean diameter of the affected adrenal gland was 25 mm (short-axis; range, 16–20 mm), and 37 mm (length; range, 24–48 mm). Contralateral adrenal glands were within normal limits in all dogs (Table 1). In dog 6, the abdominal CT scan confirmed the presence of an enlarged right adrenal gland with multiple hyperdense calcifications proximal to, but not infiltrating, the medially displaced caudal vena cava (Fig 4).

Surgical Findings

Affected adrenal glands were removed successfully via laparoscopic approach without need for celiotomy. Mean surgical time from Verres needle insertion to complete closure was 113 minutes (range, 90–150 minutes; Table 2). Mean surgical time for the right adrenal gland was 133 minutes (range, 120–150 minutes) and for the left adrenal, 99 minutes (range, 90–110 minutes). Iatrogenic injury because of trocar placement or Verres needle insertion did not occur.

In all dogs, the adrenal gland appeared friable under tension, and was partially suctioned before excision in small pieces. Despite careful manipulation, the capsule of the gland was accidentally ruptured in the first 2 dogs. In the next 5 dogs, a small window was opened in the capsule with concurrent closely positioned suction and the

Table 1. General Characteristics of Dogs Treated by Laparoscopic, Unilateral Adrenalectomy

Dog	Signalment	Signs	Abnormal Findings on CBC and Serum Chemistry (Reference Range)	Size of the Affected Gland*: Localization Other Ultrasound Abnormalities
1	14-year-old, M, 30 kg Briard	PD/PD, polyphagia, abdominal enlargement, alopecia	None	30 × 45 mm Left Mild hepatomegaly, urinary bladder distention
2	11-year-old, SF, 37 kg Labrador Retriever	Calcinosis cutis, alopecia	ALP = 4712 U/L (10–80)	29 × 36 mm: Right None
3	9-year-old, M, 13 kg Poodle	PD/PD, polyphagia, abdominal enlargement, alopecia, thin skin	Blood white cells = 22 × 10^{10}/L (6–13) ALP = 3281 U/L (10–80) Cholesterolemia = 3 g/L (0.2–2.5) Lipemia = 1.7 g/L (<0.5)	25 × 35 mm: Right Mild hepatomegaly, cholecystitis
4	10-year-old, M, 7 kg Yorkshire Terrier	PU/PD	None	38 × 38 mm: Left None
5	13-year-old, M, 20 kg Mixed Breed	PU/PD, polyphagia, abdominal enlargement, calcinosis cutis	ALP = 3423 U/L (10–80) ALT = 473 U/L (10–50)	23 × 37 mm: Left Mild hepatomegaly
6	12-year-old, SF, 12 kg Mixed Breed	PU/PD, polyphagia, abdominal enlargement	None	24 × 48 mm: Right Mild hepatomegaly
7	10-year-old, SF, 14 kg Tibetan Terrier	PU/PD, hematuria, stranguria, weakness/lethargy	Blood white cells = 18 × 10^{10}/L (6–13) ALP = 2907 U/L (10–80)	17 × 24 mm: Left Mild hepatomegaly, enlarged spleen

*Reference range for adrenal gland size: short axis 3–7.5 mm; long axis <2.4 mm.[54,55]

M, male; SF, spayed female; PU/PD, polyuria/polydipsia; ALP, alkaline phosphatase; ALT, alanine aminotransferase.

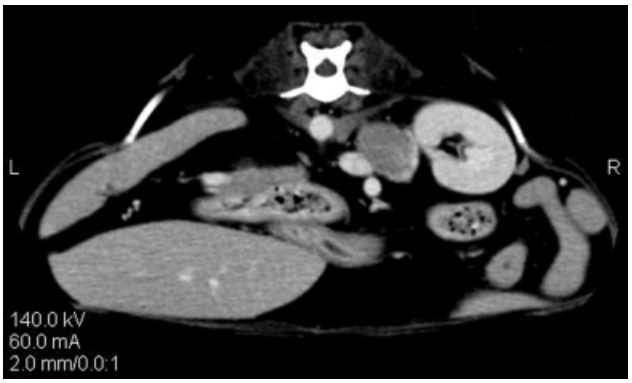

Fig 4. Preoperative computed tomography scan of dog 6 with an enlarged right adrenal gland.

necrotic semiliquid content aspirated. This technique was exploited to minimize the risk of intrasurgical rupture of the gland, with subsequent spillage of neoplastic cells. All grossly visible adrenal gland tissue was then removed. Mild hemorrhage occurred in dog 2 during dissection and was controlled by bipolar cauterization. No other perioperative complications occurred.

Postoperative Complications

In 3 dogs (dogs 1, 2, 5) subcutaneous cellulitis around the surgical portals occurred after 24 hours and resolved with hot packing within 5 days (Table 2). Dogs 3 and 4 died 2 days after surgery from respiratory complications (Table 2). Thoracic radiographs showed the presence of alveolar infiltrates and pleural effusions in both dogs; their owners declined necropsy.

Outcome

Five dogs were discharged within 3 days. Survival times for dogs 1, 2, 5–7 ranged from 7 to 25 months (mean survival time, 15.4 months). All dogs had marked improvement of clinical signs of Cushing's syndrome. Polyuria and polydipsia (dogs 1, 5–7) as well as polyphagia (dogs 1, 5, 6) recovered rapidly within the first 4 weeks after surgery. Alopecia (dogs 1, 6), and calcinosis cutis (dogs 2, 5) recovered gradually to a subnormal level within the first 2–3 months. Abdominal enlargement (dogs 1, 5, 6) improved partially. Signs of cystitis and weakness/lethargy in dog 7 resolved within 2 weeks.

Despite our recommendations, ACTH stimulation tests were not performed after surgery because of logistic reasons. Dog 1 died 7 months after surgery from unknown cause. Notably, this dog had no evidence of thoracic metastases nor clinical signs of Cushing's syndrome. Dog 2 was euthanatized 12 months after surgery because of radiographic evidence of pulmonary metastases. Dogs 5–7 were still alive at 25, 19, and 14 months (mean survival time, 19 months) after the last follow-up visit (Table 2).

Histology Findings

Adrenocortical carcinoma was diagnosed in all dogs. Histologic evidence of neoplastic emboli (vascular and/or lymphatic invasion) was observed in the adrenal gland tissue of dogs 2, 4–6.

DISCUSSION

We were able to successfully perform laparoscopic unilateral adrenalectomy without need for conversion to

Table 2. Perioperative Data and Clinical Outcome of 7 Dogs with Adrenocortical Carcinomas Treated by Laparoscopic Adrenalectomy

Dog	Surgical Complications	Postoperative Complications	Surgical Time (minutes)	Follow-up and Clinical Outcome
1	Gland rupture	Subcutaneous cellulites around portals	100	7 months Died*
2	Mild hemorrhage, gland rupture	Subcutaneous cellulites around portals	130	12 months Euthanatized†
3	None	Severe respiratory distress	120	2 days Died‡
4	None	Severe respiratory distress	90	2 days Died‡
5	None	Subcutaneous cellulites around portals	95	25 months Alive
6	None	None	150	19 months Alive
7	None	None	110	14 months Alive

*Died of causes unrelated to adrenal tumor.
†Euthanatized because of pulmonary metastasis.
‡Died of severe respiratory distress.

open laparotomy in 7 dogs with unilateral adrenal tumors (3 right-sided, 4 left-sided) without neoplastic invasion of the caudal vena cava.

Comparative human studies have shown the benefits of minimally invasive techniques for removal of benign adrenal tumors (either functional or nonfunctional) of <12 cm in size.[13–16] Potential benefits of minimally invasive approaches include decreased requirements for analgesics, fewer adrenalectomy-related complications, improved patient satisfaction, shorter hospital stays, and faster recovery periods when compared with open surgery.[14–34] Interestingly, laparoscopic ovariohysterectomy in dogs is associated with reduced postoperative pain and surgical stress compared with an open technique.[35–37] Moreover, a significantly higher nociceptive threshold as assessed by the tolerated palpation pressure was evident in dogs treated laparoscopically compared with those that had median celiotomy.[36] Finally, dogs treated with celiotomy may have significantly higher plasma cortisol levels at 1–2 hours after surgery.[36,37] It is thus posited that laparoscopic adrenalectomy may offer other potential advantages over an open technique, including limited manipulation of other abdominal organs, decreased surgical wound complications, improved postoperative comfort, as well as an excellent view of abdominal structures. This magnification could be especially useful during dissection between the right adrenal gland and the caudal vena cava.

Although transabdominal or retroperitoneal approaches have been described for human laparoscopic adrenalectomy, the lateral transabdominal approach remains the most widely used technique. Accordingly, it offers a large field of view that enables good orientation and an optimal observation of landmarks familiar from open surgical approach.[14,16–18,21,22,31,33] The retroperitoneal approach provides more direct access to the adrenal gland and can avoid abdominal adhesions in patients with previous abdominal surgery; however, dissection and exposure are more difficult, the working space is limited, and this approach does not allow a full abdominal exploration.[19,22,30,38] In the light of these caveats, as well as for body size, we chose the transabdominal laparoscopic approach for our dogs. As in human surgery,[14,19,21,22,24] our dogs were placed in lateral recumbency on the unaffected side, with a cushion placed under the *erector spinae* muscle group to raise the spine towards the surgeons standing on the dog's ventral side.

The surgical portals were placed along the paralumbar fossa using a transperitoneal approach (Fig 2), which allowed excellent exposure of the adrenal gland, as well as optimal viewing during dissection. This could be especially useful when performing dissection between the right adrenal gland and caudal vena cava that is essential to avoid entering the gland or disrupting the caudal vena cava. This is especially difficult, risky, and challenging to achieve especially for right-sided tumors, inasmuch as the right adrenal gland is extremely close to the caudal vena cava and its capsule is medially continuous with the tunica adventitia of the vein.[39]Although this complication was not observed in the 3 dogs with right-sided tumors, the possible occurrence of life-threatening hemorrhage resulting from the effraction of the caudal vena cava during right adrenal gland dissection must be seriously considered. This operative complication should be carefully discussed with owners and special precautions such as preoperative blood typing are highly recommended.

Dissection of the phrenicoabdominal vein must be carefully performed to avoid bleeding and gland trauma. We performed hemostasis of the right phrenicoabdominal vein at its junction with the caudal vena cava. Because the left phrenicoabdominal vein enters the left renal vein and does not join directly with the caudal vena cava,[39] its dissection is easier to perform. Mild hemorrhage occurred in dog 2 during the dissection of the right phrenicoabdominal vein but it was quickly controlled with bipolar cauterization without the need of blood transfusion.

Bleeding is the most common complication during and after laparoscopic adrenalectomy in humans, and accounts for $\sim 40\%$ of all complications.[16] Nonetheless, blood transfusions are required in $<5\%$ of patients.[16] In dogs 6 and 7, the use of the LigaSure® device proved useful for bleeding prevention. Accidental rupture of the adrenal capsule occurred in the first 2 dogs despite extremely careful manipulation during dissection. Whether this phenomenon occurred from lack of experience, the nature of the tumor, or both, remains unclear. Adrenal carcinomas are very friable, and ruptures have been reported even with the conventional open technique.[7] In the 5 subsequent dogs, we decided to create a little window in the capsule to perform immediate intracapsular suction of the semiliquid content, thereby avoiding the potential risks of accidental gland rupture. It should be noted, however, that this method may result in tumor seeding. Immediate close suction was thus performed thereafter. Excision of the entire gland or small pieces of all visible adrenal tissue through the 12-mm protected trocar was achieved in all dogs. Use of retrieval bags has been recommended to prevent tumor cell spillage during laparoscopic removal of tumors. In our dogs, the overall fragility of the gland would have warranted the use of retrieval bag and should be considered in the future.

The clinical consequences of tumor spillage in adrenal carcinoma remain unclear. Even in the presence of microscopic invasion into the blood vessels, regrowth is generally slow and clinical recurrence may take several years to develop.[7,40] Van Sluijs et al[7] reported a disease-free survival of 8 and 48 months for 2 of 5 dogs with a

ruptured capsule. Despite capsule gland effraction, none of the dogs had clinical signs of recurrent hyperadrenocorticism compared with 9% (2 of 22) and 29% (8 of 28) in 2 other reports.[7,40] Additionally, our data suggest that capsule gland effraction does not seem to influence the clinical outcome. Dogs 5–7 are still alive at 25, 19, and 14 months after surgery. In dog 2, death was likely because of tumor-related causes (lung metastases 12 months after surgery). In future studies, more distant dissection and the use of surgical devices as Harmonic Scalpel® or LigaSure® may help to avoid this issue.

We did not have to revert to open surgical technique. Conversion to an open procedure occurs in $\sim 2\%$ of human cases (range, 0–13%), the main indication for conversion being uncontrollable bleeding (40% of all complications).[16,41] The second most common reason for conversion to an open procedure is the presence of malignancy with local and vascular invasion as detected upon laparoscopic exploration.[16,41]

In humans, postoperative complications after laparoscopic adrenalectomy include bleeding, wound infection or hematoma, as well as thromboembolic, urinary, gastrointestinal, pulmonary, and cardiovascular problems.[16,20–27,30] Injury to peritoneal and retroperitoneal organs (liver parenchyma, spleen, pancreas, colon, lymphatic system, and adrenal gland) accounts for $<5\%$ of all complications.[15,32,33] In dogs, minor spleen injury and controllable bleeding are the most common complications being reported during laparoscopic procedures.[35,36,42] Acute pancreatitis with peritonitis has been reported to be responsible for 8–25% of mortality rates after open adrenalectomy, especially with the ventral median approach.[5,7] In our dogs, pancreatitis did not occur; however, further investigations are needed to evaluate the potential impact of this minimally invasive surgical approach on the occurrence of pancreatitis in dogs. Iatrogenic injury from trocar or Verres needle insertion did not occur in our dogs.

Causes of death after laparoscopic adrenalectomy in people include massive hemorrhage, necrotizing pancreatitis, pulmonary embolism, sepsis, and cardiopulmonary failure.[16,41] When compared with open adrenalectomy, the laparoscopic approach has been found to reduce the likelihood of perioperative complications in people undergoing adrenalectomy.[25] A positive impact of laparoscopy on intraoperative bleeding and postoperative pulmonary complications has been previously demonstrated.[19] The overall mortality rates in people vary between 0.2% and 1.2% at 30-day follow-up.[16,41] In our dog, perioperative mortality rate was 28% (2 of 7 dogs, both deaths occurring postoperatively). Although this rate may seem quite high, it is comparable with the rates of 19% (4/21),[8] 21% (6/28),[40] 28% (10/36),[7] and 60% (15/25)[5] reported previously in dogs. The major postoperative complication observed in our dogs was severe respiratory distress in 28% (2 of 7) of dogs. Both animals died 48 hours after surgery without a definitive diagnosis. Clinical signs and thoracic radiographs were compatible with pulmonary thromboembolism and/or pneumonia, both being well-known postoperative complications occurring in animals and humans suffering from hyperadrenocorticism.[1–3]

Dogs with hyperadrenocorticism undergoing adrenalectomy are at an increased risk of developing pulmonary thromboembolism.[1,2] It should be noted, however, that we were unable to perform necropsy to determine the exact causes of death. In humans, thromboembolic complications can be reduced by perioperative anticoagulation.[43] Although we did not perform routine anticoagulation in dogs with Cushing's syndrome, administration of low-dose heparin for several days after surgery may help to reduce the occurrence of embolic events. It should be noted, however, that pulmonary thromboembolism has been also reported to occur in a series of dogs administered heparin during and after open adrenalectomy.[40] To the best of our knowledge, no studies on the potential usefulness of heparin to prevent pulmonary thromboembolism in the dog have been published. Further studies are also needed to establish whether intermittent positive pressure ventilation or pneumoperitoneum may increase the likelihood of thromboembolism in Cushing's patients, regardless of the surgical procedure used. In people, laparoscopy has been shown to induce specific pathophysiologic changes in response to pneumoperitoneum, which may in turn predispose to the development of deep venous thrombosis.[44,45] We are unaware of similar studies in dogs. Given the gap of information on the incidence of venous thromboembolism after laparoscopic procedures in dogs, we believe that the need for thromboprophylaxis cannot be firmly established. Further studies are needed to understand venous thromboembolism, after cancer surgery, which remains a common and severe complication in humans.[16,41]

Laparoscopic surgery is likely to be less painful than open surgery because of smaller incision size and decreased skin and muscular trauma. Although pain scores were not evaluated in our dogs, all were standing up the day after surgery and palpation of the abdomen was not painful. Dogs were discharged 72 hours after surgery and no dog required analgesic drugs during home stay. Moreover, no wound complications other than mild cellulitis were observed even in the presence of some severe preexisting skin lesions. Notably, abdominal incision dehiscence has been reported to occur in 10% of cases after open adrenalectomy.[40]

Disadvantages or problems associated with laparoscopic adrenalectomy may include increased surgical time, the need for specific instrumentation, technical difficulties, and the occurrence of intraoperative compli-

cations during dissection (mild bleeding and gland rupture). As for other laparoscopic techniques, laparoscopic adrenalectomy has longer surgical times and is more technically demanding than the conventional open techniques, at least until the learning curve allows the surgeon's full confidence. In our dogs, mean surgical time for laparoscopic adrenalectomy (from Verres needle insertion to complete closure) was 113 minutes (range, 90–150 minutes). Given differences in anatomic location, mean surgical time for the right adrenal gland (133 minutes; range, 120–150 minutes) was longer than for the left adrenal gland (99 minutes; range, 90–110 minutes). Surgical time with an open approach may be shorter and reportedly ranges between 100 and 180 minutes.[4,6] As for any minimally invasive procedure, laparoscopic adrenalectomy requires specific and more expensive surgical instrumentation; however, use of reusable instruments may decrease instrumentation costs.

In human surgery, the role of laparoscopy in the management of adrenocortical cancer remains controversial. Because these tumors are usually very large, open adrenalectomy is still preferred by some surgeons. On the other hand, laparoscopic adrenalectomy is regarded by other surgeons as the "gold standard" for treatment of adrenal tumors (adrenocortical carcinoma and malignant pheochromocytoma) in humans, at least in the absence of either local or vascular invasion.[13–16,24,26,27,31,33,34,46,47]

Portal site tumor recurrence and occurrence of intra-abdominal carcinomatosis from laparoscopic adrenalectomy have been repeatedly reported with malignant adrenal tumors.[48–50] In contrast, other authors have not reported local or portal site recurrence after laparoscopic adrenalectomy in malignant tumors with negative margins.[51] In patients with adrenocortical cancer, a 60% locoregional recurrence rate has been reported, which is similar to the rate reported for open adrenalectomy.[52] Despite the opening of the gland capsule in our dogs, no clinical signs related to hyperadrenocorticism because of either a local or a portal site recurrence were observed.

Adrenocortical carcinoma was diagnosed in all of our dogs. Histologic evidence of neoplastic emboli in the adrenal gland tissue analyzed (vascular and/or lymphatic invasion) was observed in 4 dogs (dogs 2, 4–6). It is worth noting, however, that this phenomenon does not seem to influence clinical outcome. Preoperative differentiation between adrenocortical adenoma and carcinomas is often difficult in the absence of metastases or obvious invasion. No imaging test can be consistently used to distinguish between benign and malignant adrenal tumors in dogs.[53]

Out of 5 discharged dogs (1, 2, 5–7), 2 survived for 7 and 12 months surgery (dogs 1, 2), and 3 are still alive (dogs 5–7) at 24, 19 and 14 months after surgery, respectively (mean survival time, 19 months). Mean published survival time for adrenocortical tumors treated by adrenalectomy in the dog is 20–22 months.[3,4,6–10] Given the small number of dogs in our series, however, these results must be interpreted cautiously.

Ideal candidates for laparoscopic adrenalectomy are dogs with adrenal masses and confined tumors, in the absence of caudal vena cava or surrounding tissues involvement, without respiratory or vascular problems, and no evidence of metastasis. Potential contraindications to the laparoscopic approach may include the presence of large and/or invasive tumors, small animal size (<7 kg), presence of obesity, evidence of metastasis, concomitant lung and/or heart disease, lack of surgical experience. Theoretically, large noninvasive tumors may be excised by experienced laparoscopic surgeons by using retrieval bags and a surgical mixer.

We conclude that laparoscopic adrenalectomy is feasible in dogs with unilateral adrenal tumors not involving the caudal vena cava. Although the technique gave promising results even in the presence of gland rupture, technical progresses should be keenly pursued to avoid capsule effraction. Compared with traditional open surgery, laparoscopic adrenalectomy may offer several advantages including decreased pain, better observation, reduced risk of dehiscence and postoperative wound complications, as well as shorter hospitalization times. Further studies in dogs are warranted to compare the short- and long-term results of laparoscopic adrenalectomy with either the ventral median or retrocostal open approaches.

ACKNOWLEDGMENTS

The authors would like to thank Dr. Dominique Heripret, Dr. F. Zeugzwetter, and Dr. Laurent Findji for their participation in the study series, and Dr. Enzo Emanuele for expert editorial assistance.

REFERENCES

1. Feldman EC, Nelson RW: Hyperadrenocorticism (Cushing's syndrome), in Canine and Feline Endocrinology and Reproduction. Philadelphia, PA, Saunders, 2003, pp 254–357
2. Reusch CE: Hyperadrenocorticism, in Ettinger SJ, Feldman EC (eds): Textbook of Veterinary Internal Medicine (ed 6), Vol 2. St. Louis, MO, Elsevier Saunders, 2005, pp 1592–1612
3. Bichard SJ: Adrenalectomy, in Slatter DH (ed): Textbook of Small Animal Surgery (ed 3), Vol 2. Philadelphia, PA, Saunders, 2003, pp 1694–1699
4. Johnston DE: Adrenalectomy via retroperitoneal approach in dogs. J Am Vet Med Assoc 170:1092, 1977
5. Scavelli TD, Peterson TD, Matthiesen DT: Results of surgical treatment for hyperadrenocorticism caused by adrenal

neoplasia in the dog: 25 cases (1980–1984). J Am Vet Med Assoc 189:1360–1364, 1986
6. Emms SG, Johnston DE, Eigenmann JE, et al: Adrenalectomy in the management of canine hyperadrenocorticism. J Am Anim Hosp Assoc 23:557–564, 1987
7. Van Sluijs FJ, Sjollema BE, Voorhout G, et al: Results of adrenalectomy in 36 dogs with hyperadrenocorticism caused by adrenocortical tumor. Vet Q 17:113–116, 1995
8. Anderson CR, Birchard SJ, Powers BE, et al: Surgical treatment of adrenocortical tumors: 21 cases (1990–1996). J Am Anim Hosp Assoc 37:93–97, 2001
9. Ter Haar G, Dierikx CM, Veneberg RE, et al: Learning curve in retroperitoneal adrenalectomy; results of 43 adrenalectomies for treatment of adrenocortical tumors, in Proceedings of the European College of Veterinary Surgeon, Lyon, France, 2005, Vol 14, pp 334–337 (abstract)
10. Brockman DJ: Making adrenalectomy less stressful, Proceedings of the 16th American College of Veterinary Surgeons Symposium, Washington, DC, October 2006
11. Higashihara E, Tanaka Y, Horie S, et al: A case report of laparoscopic adrenalectomy. Nippon Hinyokika Gakkai Zasshi 83:1130–1133, 1992
12. Gagner M, Lacroix A, Bolte E: Laparoscopic adrenalectomy in Cushing's syndrome and phaeochromocytoma. N Engl J Med 327:1033, 1992
13. Porpiglia F, Destefanis P, Fiori C, et al: Does adrenal mass size really affect safety and effectiveness of laparoscopic adrenalectomy? Urology 60:801–805, 2002
14. Lal G, Duh QY: Laparoscopic adrenalectomy—indications and technique. Surg Oncol 12:105–123, 2003
15. Cougard P, Spie R, Osmak L, et al: Exérèse laparoscopique des volumineuses tumeurs de la surrénale. Ann Chir 129:503–507, 2004
16. Gumbs AA, Gagner M: Laparoscopic adrenalectomy. Best Pract Res Clin Endocrinol Metab 20:483–499, 2006
17. Mancini F, Mutter D, Peix JL, et al: Expérience de la surrénalectomie en 1997. A propos de 247 cas. Etude prospective multicentrique de l'association francophone de chirurgie endocrinienne. Chirurgie 124:368–374, 1999
18. Imai T, Kikumori T, Funahashi H, et al: Surgical management of Cushing's syndrome. Biomed Pharmacother 54(Suppl 1): 140–145, 2000
19. Yoneda K, Shiba E, Watanabe T, et al: Laparoscopic adrenalectomy: lateral transabdominal approach vs posterior retroperitoneal approach. Biomed Pharmacother 54(Suppl 1): 215–219, 2000
20. Brunt LM: The positive impact of laparoscopic adrenalectomy on complications of adrenal surgery. Surg Endosc 16:252–257, 2002
21. Marescaux J, Mutter D: Laparoscopic transabdominal adrenalectomy: left and right. Asian J Surg 26:19, 2003
22. Hallfeldt KK, Mussack T, Trupka A, et al: Laparoscopic lateral adrenalectomy versus open posterior adrenalectomy for the treatment of benign adrenal tumors. Surg Endosc 17:264–267, 2003
23. Jacobsen NE, Campbell JB, Hobart MG: Laparoscopic versus open adrenalectomy for surgical adrenal disease. Can J Urol 10:1995–1999, 2003
24. Kwok K, Ng C, Yau LC: Applicability and outcome of laparoscopic adrenalectomy. Asian J Surg 26:71–75, 2003
25. Gonzalez R, Smith CD, McClusky DA III, et al: Laparoscopic approach reduces likelihood of perioperative complications in patients undergoing adrenalectomy. Am Surg 70:668–674, 2004
26. Emerlau D, Vallée V, Tauzin-Fin P, et al: Morbidity of unilateral and bilateral laparoscopic adrenalectomy according to the indication. Report of a series of 100 consecutive cases. Prog Urol 15:626–631, 2005
27. Ito K, Asano T, Sumitomo M, et al: Clinical experience of laparoscopic adrenalectomy: the national defense medical college experience. Hinyokika Kiyo 51:783–788, 2005
28. Lifante JC, Cenedese JM, et al: Evolution de la prise en charge de la pathologie surrénalienne depuis l'avènement de la laparoscopie. Une étude rétrospective de 220 patients. Ann Chir 130:547–552, 2005
29. Plaggemars HJ, Targarona EM, Couwelaar G, et al: What has changed in adrenalectomy? From open surgery to laparoscopy? Cir Esp 77:132–138, 2005
30. Aguilera A, Alonso S, Cansino R, et al: Retroperitoneal laparoscopic surgery: single surgeon experience. Eur Urol Suppl 5:983–988, 2006
31. Zacharias M, Haese A, Jurczok A, et al: Transperitoneal laparoscopic adrenalectomy: outline of the preoperative management, surgical approach, and outcome. Eur Urol 49:448–459, 2006
32. Ramachandran MS, Reid JA, Dolan SJ, et al: Laparoscopic adrenalectomy versus open adrenalectomy: results from a retrospective comparative study. Ulster Med J 75:126–128, 2006
33. Kornprat P, Langner C, Mischinger HJ: Laparoscopic adrenalectomy by the transperitoneal approach and typical complications: own experience and review of current literature. Internet J Surg 7, 2006 (www.ispub.com)
34. Zografos GN, Markou A, Ageli C, et al: Laparoscopic surgery for adrenal tumors: a retrospective analysis. Hormones 5:52–56, 2006
35. Davidson EB: Comparison of laparoscopic ovariohysterectomy and ovariohysterectomy in dogs. Vet Surg 33:62–69, 2004
36. Hancock RB, Lanz OI, Waldron DR, et al: Comparison of postoperative pain after ovariohysterectomy by harmonic scalpel-assisted laparoscopy compared with median celiotomy and ligation in dogs. Vet Surg 34:273–282, 2005
37. Devitt CM, Cox RE, Hailey JJ: Duration, complications, stress, and pain of open ovariohysterectomy versus a simple method of laparoscopic-assisted ovariohysterectomy in dogs. J Am Vet Med Assoc 227:921–927, 2005
38. Terachi T, Yoshida O, Matsuda T, et al: Complications of laparoscopic and retroperitoneoscopic adrenalectomies in 370 cases in Japan: a multi-institutional study. Biomed Pharmacother 54(Suppl 1): 211–214, 2000
39. Evans HE: The endocrine system (adrenal gland), in Evans HE (ed): Miller's Anatomy of the Dog (ed 3). Philadelphia, PA, Saunders, 1993, pp 574–579

40. Kyles AE, Feldman EC, De cock HEV, et al: Surgical management of adrenal gland tumors with and without associated tumor thrombi in dogs: 40 cases (1994–2001). J Am Vet Med Assoc 223:654–662, 2003
41. Assalia A, Gagner M: Laparoscopic adrenalectomy. Br J Surg 91:1259–1274, 2004
42. Van Goethem BE, Rosenveldt KW, Kirpensteijn J: Monopolar versus bipolar electrocoagulation in canine laparoscopic ovariectomy: a nonrandomized, prospective, clinical trial. Vet Surg 32:464–470, 2003
43. Boscaro M, Sonino N, Scarda A, Barzon L, et al: Anticoagulant prophylaxis markedly reduces thromboembolic complications in Cushing's syndrome. J Clin Endocrinol Metab 87:3662, 2002
44. Gutt CN, Oniu T, Mehrabi A, et al: Circulatory and respiratory complications of carbon dioxide insufflation. Digest Surg 21:95–105, 2004
45. Holzheimer RG: Laparoscopic procedures as a risk factor of deep venous thrombosis, superficial ascending thrombophlebitis and pulmonary embolism—case report and review of literature. Eur J Med Res 9:417–422, 2004
46. Jarolim L, Breza J, Wunderlich H: Adrenal tumours. Eur Urol 43 (Curriculum Urol I–X) 2003
47. Cobb WS, Kercher KW, Sing RF, et al: Laparoscopic adrenalectomy for malignancy. Am J Surg 189:405–411, 2005
48. De Canniere L, Michel L, Hamoir E, et al: Multicentric experience of the Belgian group for endoscopic surgery (BGES) with endoscopic adrenalectomy. Surg Endosc 11:1065–1067, 1997
49. Suzuki K, Ushiyama T, Mugiya S, et al: Hazards of laparoscopic adrenalectomy in patients with adrenal malignancy. J Urol 158:2227, 1997
50. Iacconi P, Bendinelli C, Miccoli P, et al: A case of Cushing's syndrome due to adrenocortical carcinoma with recurrence 19 months after laparoscopic adrenalectomy. J Urol 161:1580–1581, 1999
51. Heniford DT, Arca MJ, Walsh RM, et al: Laparoscopic adrenalectomy for cancer. Semin Surg Oncol 16:293–306, 1999
52. Vassilopoulou-Sellin R, Schultz PN: Adrenocortical carcinoma. Clinical outcome at the end of 20th century. Cancer 92:1113–1121, 2001
53. Labelle P, Kyles AE, Farver TB, et al: Indicators of malignancy of canine adrenocortical tumors: histopathology and proliferation index. Vet Pathol 41:490–497, 2004
54. Barthez PY, Nyland TG, Feldman EC: Ultrasonographic evaluation of the adrenal glands in dogs. J Am Vet Med Assoc 207:1180, 1995
55. Nyland TG: Ultrasonography of the urinary tract and adrenal glands, in Nyland TG, Mattoon JS (eds): Veterinary Diagnostic Ultrasound. Philadelphia, PA, 1995, p 112

BSAVA BRITISH SMALL ANIMAL VETERINARY ASSOCIATION

CASE REPORT

Thoracoscopic foreign body removal and right middle lung lobectomy to treat pyothorax in a dog

M. Jiménez Peláez and C. Jolliffe*

Soft Tissue Surgery Unit, Animal Health Trust, Kentford, Newmarket, Suffolk CB8 7UU

*Anaesthesia and Intensive Care Unit, Animal Health Trust, Kentford, Newmarket, Suffolk CB8 7UU

M. Jiménez Peláez's current address is Davies Veterinary Specialists, Manor Farm Business Park, Higham Gobion, Herts SG5 3HR

A three-year-old, 30-kg, spayed female German wirehaired pointer was presented for coughing, pyrexia and lethargy. Thoracic radiographs showed mild right-sided pleural effusion, moderate pneumothorax and a pulmonary lesion in the right middle or caudal lung lobe. A diagnosis of pyothorax was established by fine needle aspiration of the pleural effusion. Thoracoscopic exploration was performed using one-lung ventilation. A vegetal foreign body (grass awn) and an abscess were observed in the distal part of the right middle lung lobe. The foreign body was removed and a right middle lung lobectomy was performed, both thoracoscopically. No complications were noted. The dog was discharged 48 hours after surgery, and no recurrence of the clinical signs was observed during the follow-up time period (three years and three months). Thoracoscopy is a minimally invasive alternative to thoracotomy to explore and successfully treat some non-chronic pyothoraces in dogs, including lesions affecting the right middle lung lobe.

Journal of Small Animal Practice (2012) **53**, 240–244
DOI: 10.1111/j.1748-5827.2011.01175.x

Accepted: 12 December 2011; Published online: 13 February 2012

INTRODUCTION

Pyothorax, characterised by the presence of a pleural exudate (whether it be septic or not), is a common cause of pleural effusion (Mellanby and others 2002) and a life-threatening disease in dogs.

The presence of an intrathoracic foreign body is an uncommon finding in pyothorax (Demetriou and others 2002). However, surgery (thoracotomy) is warranted in cases of large inhaled foreign bodies and/or mediastinal or pulmonary lesions (Rooney and Monnet 2002, Scott and Macintire 2003b, Johnson and Martin 2007). Potential disadvantages associated with intercostal thoracotomy and sternotomy include wound complications, long recovery and postoperative pain (Ringwald and Birchard 1989, Pascoe and Dyson 1993, Burton and White 1996, Walsh and others 1999, Mellanby and others 2002, Dunning 2003, Orton 2003, Rooney and others 2004, Moores and others 2007).

Thoracoscopy is widely used in human medicine and preferred, when applicable, to open thoracotomy because of decreased tissue trauma, shorter intraoperative time, reduced postoperative pain, minimised pulmonary dysfunction and shorter recovery times (Landrenau and others 1993).

CASE REPORT

A three-year-old, 30-kg, spayed female German wirehaired pointer was presented with a 2-day history of pyrexia and lethargy. An episode of coughing was observed 6 days before presentation but resolved without treatment. At the time of admission, the dog was depressed, tachycardic, tachypnoeic and hyperthermic (39·5°C). Survey thoracic radiographs showed a mild right pleural effusion, moderate pneumothorax and a 2-cm poorly marginated interstitial opacity suspected to be located in the right middle or caudal lung lobe (Fig 1). Thoracic ultrasound confirmed these findings and a sample of pleural fluid was taken under ultrasonographic guidance; cytology and bacteriology (aerobic and anaerobic) were performed. Cytology of the pleural fluid was consistent with pyothorax (numerous toxic neutrophils, several large colonies of coccoid extra-cellular bacteria, eosinophils and mast cells). Complete haematology, biochemistry,

JSAP JOURNAL OF SMALL ANIMAL PRACTICE

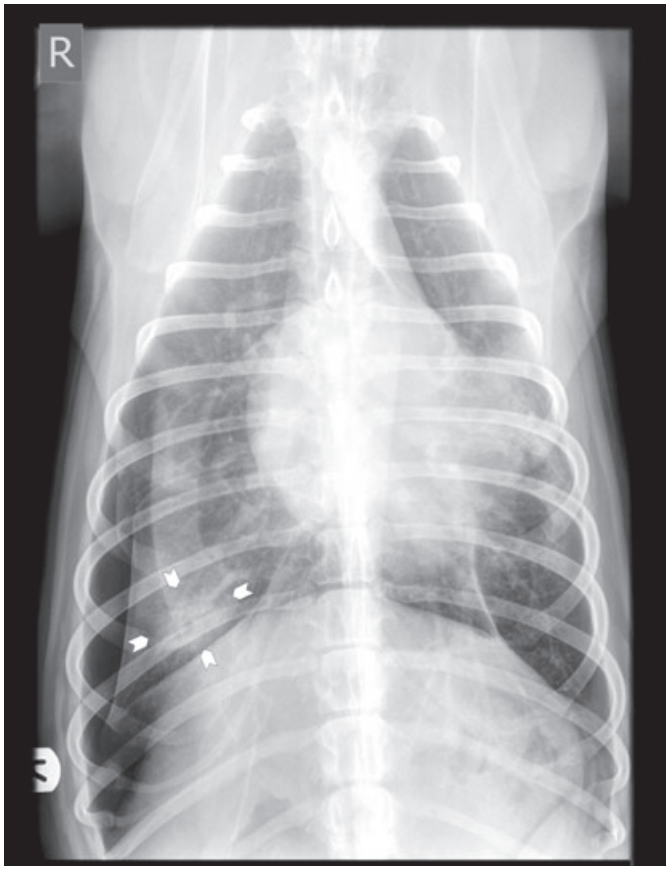

FIG 1. Dorso-ventral thoracic radiograph showing a pneumothorax and an ill-defined interstitial opacity (chevrons) in the right caudal lung field

electrolytes, coagulation profile and a urinary culture were performed. A mild neutrophilia and a mild lymphopenia were the only abnormalities found.

Immediate medical treatment included placement of a thoracic drain in the right hemithorax, fluid therapy using crystalloids at 4 mL/kg/hour (Hartmann's solution, Aqupharm No.11, Animalcare), administration of 15 mg/kg of metronidazole (Metronidazole; Baxter) intravenously (iv) every 12 hours, 20 mg/kg of amoxicillin-clavulanic acid (Augmentin; GlaxoSmithKline) iv every 6 hours, 0·1 mg/kg of meloxicam (Metacam; Boehringer Ingelheim) orally once a day and 0·2 mg/kg of methadone hydrochloride (Physeptone; Martindale) subcutaneously (SC) every 4 to 6 hours as required according to the estimated levels of pain. After initial stabilisation, an exploratory thoracoscopy was planned the following day.

Thoracoscopy

Thoracoscopic exploration of the right hemithorax was performed using a one-lung ventilation technique with a 37-Fr right double-lumen endobronchial tube (Blue Line Endobronchial tube, Portex Ltd) endoscopically placed. The left lung and the right cranial lung lobe were ventilated mechanically using a volume-controlled ventilator (Merlin Small Animal Ventilator; Vetronic). The right middle and caudal lung lobes were not ventilated and remained inflated.

The dog was positioned in left lateral recumbency, and a cushion was placed under the dorsal part of the left hemithorax to raise the spine towards the surgeons standing by the animal's ventral side. The right hemithorax was clipped and surgically prepared. The video monitor was positioned on the dorsal side of the dog. A 3-portal technique was used. Two 5·5-mm cannulae were placed: one on the ventral third of the 8th intercostal space (thoracoscope) and one on the dorsal third of the 10th intercostal space (instrumental portal) (Fig 2). One 11·5-mm cannula was placed on the ventral third of the sixth intercostal space (instrumental portal and stapling device).

The chest tube was removed just before starting the surgery. A 0·5-cm skin incision was made in the ventral third of the eighth intercostal space. Halsted haemostat forceps were used to bluntly penetrate the thoracic wall and a 5-mm trocar unit consisting of a threaded flexible sleeve around a blunt-tipped obturator (Thoracoport Soft; Covidien Autosuture), was inserted into the thoracic cavity. A 5-mm, 0-degree thoracoscope (Karl Storz-Endoskope) was introduced through this cannula and a second 5-mm similar portal (instrumental) was created in a same manner, but under video control, in the dorsal third of the 10th intercostal space. Exploratory thoracoscopy was performed on the right hemithorax helped with a 5-mm atraumatic Babcock forceps (Optec) passed through the second portal. Abnormalities encountered were a mild sero-haemorrhagic pleural effusion, a visceral pleuritis and a focal lesion (1·5-cm diameter) on the caudal aspect of right middle lung lobe, consistent with abscessation/foreign body reaction. Adhesions were found between the pulmonary lesion and ventral mediastinal tissues (Fig 3). A vegetal foreign body (grass awn) was found protruding between the pulmonary lesion and the mediastinal adhesions to the lesion.

A third 11·5-mm trocar (Thoracoport Soft; Covidien Autosuture) was introduced on the ventral third of the sixth intercostal space, and a 5-mm Maryland endoscopic dissector (Optec) was introduced. The foreign body was removed (Fig 4), and the mediastinal adhesions to the parenchymal lesion were excised using a 5-mm feedback-controlled, bipolar tissue-sealing system, the LigaSure™ device (LigaSure™ Lap 5-mm;

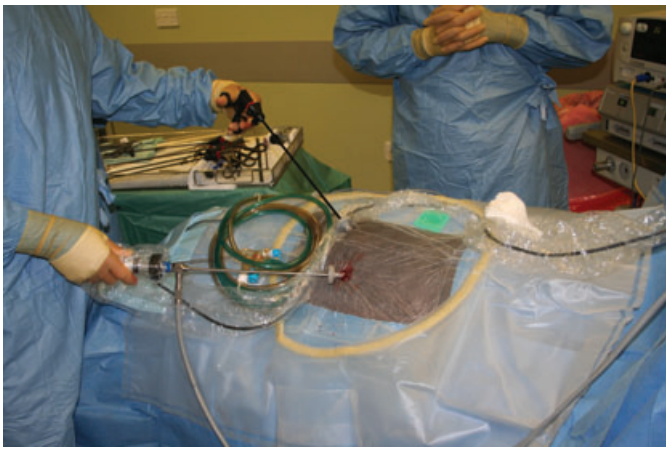

FIG 2. Positions of the first two portals for exploratory thoracoscopy through a right intercostal approach

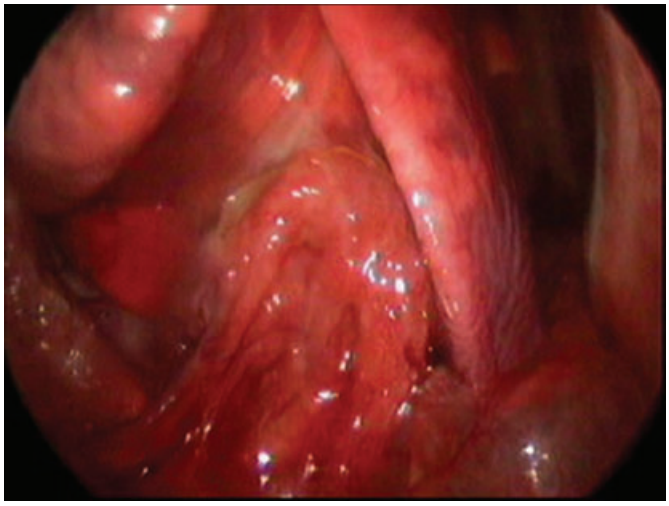

FIG 3. Intraoperative thoracoscopic view of the adhesions between the mediastinal pleura and the lung lobe lesion and foreign body

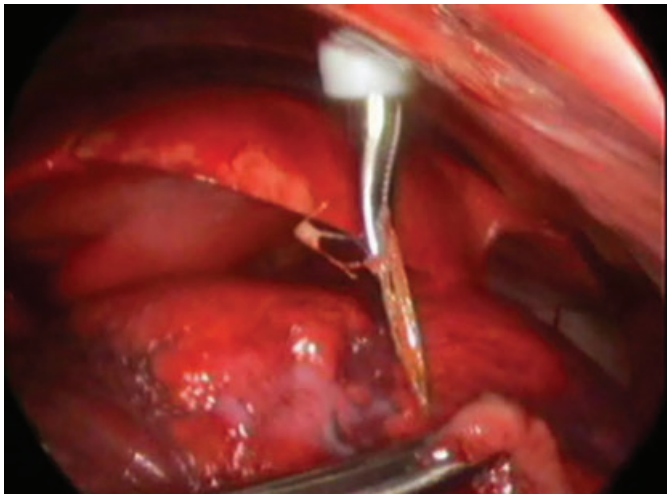

FIG 4. Vegetal foreign body (grass awn) removal

FIG 5. Caudal retraction of the right middle lung lobe and placement of an endoscopic gastrointestinal anastomosis (endoGIA) stapler for lung lobectomy

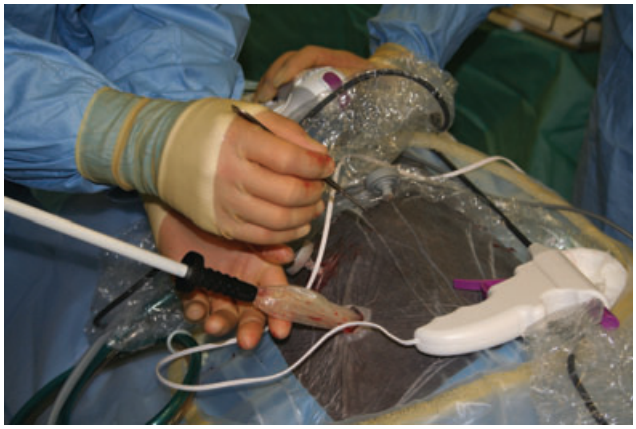

FIG 6. Extraction of the retrieval bag through the extended 11.5-mm portal, without retraction of the ribs

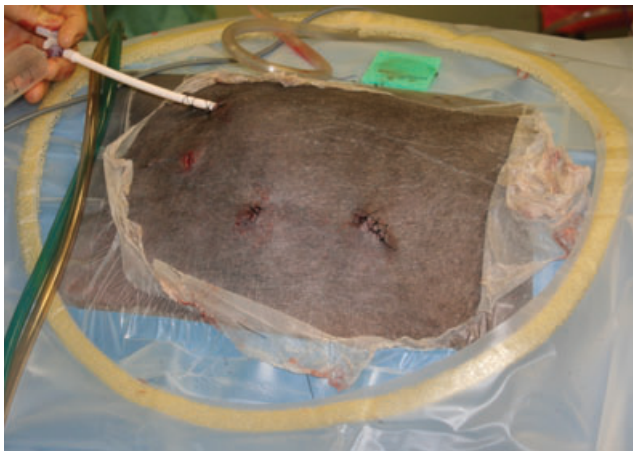

FIG 7. Postoperative view of portal site incisions and secured chest drain

Valleylab-Covidien). A right middle lung lobectomy was then performed thoracoscopically using a 45-mm endoscopic gastrointestinal anastomosis stapler with a 3·5-mm cartridge (Endo-GIA; Covidien Autosuture) (Fig 5). The resected lung lobe was placed in an endoscopic retrieval bag (Endo-retrieval pouch; Cory bros) and was retrieved through a 2 to 3-cm incision extension of the 11·5-mm instrumental portal (Thoracoport Soft; Covidien Autosuture), without retraction of the ribs (Fig 6). No intraoperative complication was noted, and no conversion to open surgery was required. A chest tube (Argyle™; Covidien Kendal) was placed under thoracoscopic control. Pulmonary exclusion was discontinued and the collapsed lung lobes were gradually re-inflated using positive-pressure ventilation. A thoracic lavage was performed using the chest tube and an endoscopic suction-irrigation device with 1 litre of warm Hartmann's solution. Air seal from the lobectomy site was verified while thoracic lavage was being performed. Portals were closed in a routine manner (Fig 7). The duration of the surgery was 50 minutes. Intercostal nerve blocks were performed on spaces adjacent to the portal sites using a total dose of 2 mg/kg of 0·5% bupivacaine (Marcain; Astrazeneca).

Immediate postoperative thoracic radiographs showed a mild residual pneumothorax.

The lung lobe removed was submitted for histology, which was consistent with multi-focal pyogranulomatous pneumonia.

Bacteriology results (aerobic and anaerobic cultures) were negative for both urine and pleural effusion samples.

Postoperative care

The dog recovered from surgery without complications. A few hours after surgery, it was ambulatory without any discomfort and there was no respiratory distress. The thoracostomy tube was drained as required and was removed 48 hours after the surgery as minimal (<2 mL/kg/24 hours) amounts of non-septic sero-haemorragic fluid, and no air were retrieved. The dog was discharged the day following drain removal with a 10-day prescription of 15 mg/kg of metronidazole orally every 12 hours, 20 mg/kg of amoxicillin-clavulanic acid orally every 12 hours and 0·1 mg/kg of meloxicam orally once a day. Thoracic radiographs repeated before discharge were within normal limits.

Follow-up

Thoracic radiographs were performed four weeks postoperatively, and no abnormality was observed. At the time of writing this manuscript (three years and three months postoperatively), no recurrence of clinical signs have been observed.

DISCUSSION

The identification and removal of a thoracic foreign body and a right middle lung lobectomy were successfully performed exclusively by a thoracoscopic approach in this case. To the authors' knowledge, this is the first time that thoracoscopic removal of the right middle lung lobe has been reported.

In small animals, the use of thoracoscopy for diagnostic and therapeutic procedures has gained in popularity over the last 10 years (Jackson and others 1999, McCarthy 1999, Potter and Hendrickson 1999, Walton 1999, Isakov and others 2000, Dupre and others 2001, McPhail and others 2001, Walton 2001, Kovac and others 2002, Radlinsky and others 2002, Brissot and others 2003, Borenstein and others 2004, Lansdowne and others 2005, McCarthy and Monnet 2005, Mayhew and Friedberg 2008). Among indications, thoracoscopy has successfully been used to determine the aetiology of pleural effusion in dogs and cats (Kovak and others 2002), and pyothorax was documented to be one of the most common causes of pleural effusions in dogs in one study (Mellanby and others 2002).

In this case report, the exact location of the pulmonary lesion (right middle or the right caudal lung lobe) could not be determined preoperatively. However, this patient presented a pyothorax with a visible radiographic pulmonary lesion, which is one of the indications for surgical treatment (Rooney and Monnet 2002, Scott and Macintire 2003b, Johnson and Martin 2007). Computed tomography (CT) was not available in this institution at the time of presentation of this case. CT has been reported to detect more sites of abnormality, determine the correct site of abnormality and trace the path of the foreign body more accurately than with radiographs in cases of migrating intrathoracic grass awns in dogs and cats (Schultz and Zwingenberger 2008).

A thoracoscopic right lateral approach was used because only the pulmonary parenchyma on right side appeared to be affected. In addition, lateral recumbency with intercostal portal placement is the preferred technique for lung lobectomy (McCarthy and Monnet 2005).

To improve visibility, surgical exposure and size of the operating field, selective ventilation, allowing the right middle, caudal and accessory lung lobes to collapse, was used. In this case, a double lumen endobronchial tube (Blue Line Endobronchial tube; Portex Ltd.) was chosen because it was readily available.

Thoracoscopy allowed excellent vision and accurate localisation of the abnormal parenchyma, on the mediastinal surface distally on the right middle lung lobe, with local adhesions to the ventral mediastinum and a grass awn. Thoracocopic lung lobectomy has been previously described (Zaal and others 1997, Garcia and others 1998, Potter and Hendrickson 1999, Lansdowne and others 2005). However, a right middle lung lobectomy has not been previously reported. Poor access and insufficient working space to manipulate the instruments and the middle lung lobe for safe application of staples have been previously reported as the main problems encountered during attempting thoracoscopic excision of this lobe (Lansdowne and others 2005). Selective ventilation and specific positioning of portals were helpful to perform the procedure. The instrumental portal placed dorsally in the 10th intercostal space was used to pull the middle lung lobe caudally which helped for its exposition and resection.

By performing the procedure thoracoscopically, some potential disadvantages associated with an open surgical approach, which include high morbidity, wound complications, long recovery and postoperative pain, could be minimised. A study demonstrated significantly higher pain score in dogs undergoing intercostal thoracotomy *versus* dogs undergoing thoracoscopy for partial pericardiectomy (Walsh and others 1999). Our patient was subjectively very comfortable postoperatively. Several hours after surgery, it was standing up and walking without any visible discomfort, was not showing any signs of respiratory distress and was eating well. No pain was noted on palpation of either the thorax or the wounds.

In this case, assessment of potential thoracic adhesions had to be judged based on the thoracic radiographs, the thoracic ultrasound and the acute onset of the condition. However, adhesions can be frequently missed on radiographs and ultrasound. Therefore, we would recommend selecting suitable candidates for thoracoscopic exploration on the basis of a CT scan of the chest. Chronic pyothorax with extensive adhesions is considered to be a contraindication for thoracoscopy. Multiple pleural adhesions are reported to impair adequate vision of the cavity and substantially increase the risks of the procedure (Walsh and others 1999, McCarthy and Monnet 2005).

Disadvantages associated with thoracoscopy may include increased surgical time, the need for specific instrumentation and technical difficulties. As for other thoracoscopic techniques,

thoracoscopic lung lobectomy may have longer surgical times and be more technically demanding than the conventional open techniques. These factors are likely to improve with operator experience and skill. The surgical time for this procedure (exploration, foreign body removal, mediastinal local resection and right middle lung lobectomy) was less than 60 minutes. This is reasonably comparable to open thoracotomies.

CONCLUSION

When adhesions are unlikely (acute pyothorax) or ruled out by advanced imaging, thoracoscopy should be considered an alternative option to thoracotomy to explore and to treat dogs presented with acute pyothorax. Using one-lung ventilation, thoracoscopic right middle lung lobectomy was feasible. It was associated with minimal postoperative pain, no morbidity and excellent vision allowing definitive diagnosis and effective treatment.

Acknowledgements

The authors would like to thank Mr James Gasson for his technical assistance during the surgery, Dr Julien Labruyère for imaging assistance, Dr Nicolas Girard and the AHT staff for assistance with case management during the postoperative period and Drs Andy Sparkes, David Thomson and Gilles Dupré for reviewing the manuscript.

Conflict of interest

None of the authors of this article has a financial or personal relationship with other people or organisations that could inappropriately influence or bias the content of the paper.

References

Borenstein, N., Behr, L., Chetboul, V., Tessier, D., Nicole, A., Jacquet, J., Carlos, C., Retortillo, J., Fayolle, P., Pouchelon, J. L., Daniel, P. & Laborde, F. (2004) Minimally invasive patent ductus arteriosus occlusion in 5 dogs. *Veterinary Surgery* **33**, 309-313

Brissot, H. N., Dupre, G. P., Bouvy, B. M. & Paquet, L. (2003) Thoracoscopic treatment of bullous emphysema in 3 dogs. *Veterinary Surgery* **32**, 524-529

Burton, C. A. & White, R. N. (1996) Review of the technique and complications of median sternotomy in the dog and cat. *Journal of Small Animal Practice* **37**, 516-522

Demetriou, J. L., Foale, R. D., Ladlow, J., McGrotty, Y., Foulkner, J. & Kirby, B. M. (2002) Canine and feline pyothorax: a retrospective study of 50 cases in the UK and Ireland. *Journal of Small Animal Practice* **43**, 388-394

Dunning, D. (2003) Surgical wound infection and the use of antimicrobials. In: Textbook of Small Animal Surgery. 3rd edn. Eds D. Slatter. W. B. Saunders, Philadelphia, PA, USA. pp 119-120

Dupre, G. P., Corlouer, J. P. & Bouvy, B. (2001) Thoracoscopic pericardectomy performed without pulmonary exclusion in 9 dogs. *Veterinary Surgery* **30**, 21-27

Garcia, F., Prandi, D., Pena, T., Franch, J., Trasserra, O. & De La Fuente, J. (1998) Examination of the thoracic cavity and lung lobectomy by means of thoracoscopy in dogs. *Canadian Veterinary Journal* **39**, 285-291

Isakov, K., Fowler, D. & Walsh, P. (2000) Video-assisted thoracoscopic division of the ligamentum arteriosum in two dogs with persistent right aortic arch. *Journal of the American Veterinary Medical Association* **217**, 1333-1336

Jackson, J., Richter, K. P. & Launer, D. P. (1999) Thoracoscopic partial pericardectomy in 13 dogs. *Journal of Veterinary Internal Medicine* **13**, 529-544

Johnson, M. S. & Martin, M. W. S. (2007) Successful medical treatment of 15 dogs with pyothorax. *Journal of Small Animal Practice* **48**, 12-16

Kovac, J. R., Ludwig, L. L., Bergman, P. J., Baer, K. E. & Noone, K. E. (2002) Use of thoracoscopy to determine the etiology of pleural effusion in dogs and cats: 18 cases (1998-2001). *Journal of the American Veterinary Medical Association* **221**, 990-994

Landrenau, R. J., Hazelrigg, S. R., Mack, M. J., Dowling, R. D., Burke, D., Gavlick, J., Perrino, M. K., Ritter, P. S., Bowers, C. M. & Defino, J. (1993) Postoperative pain-related morbidity: video-assisted thoracic surgery versus thoracotomy. *The Annals of the Thoracic Surgery* **56**, 1285-1289

Lansdowne, J. L., Monnet, E., Twedt, D. C. & Dernell, W. S. (2005) Thoracoscopic lung lobectomy for the treatment of lung tumors in dogs. *Veterinary Surgery* **34**, 530-535

Mayhew, P. D. & Friedberg, J. S. (2008) Video-assisted thoracoscopic resection of noninvasive thymomas using one-lung ventilation in two dogs. *Veterinary Surgery* **37**, 756-762

McCarthy, T. C. (1999) Diagnostic thoracoscopy. *Clinical Techniques in Small Animal Practice* **14**, 213-219

McCarthy, T. C. & Monnet, E. (2005) Diagnostic and operative thoracoscopy. In: Veterinary Endoscopy for the Small Animal Practitioner. Eds T. C. McCarthy. Elsevier Saunders, St. Louis, MO, USA, pp 229-278

McPhail, C. M., Monnet, E. & Twedt, D. C. (2001) Thoracoscopic correction of persistent right aortic arch in a dog. *Journal of the American Animal Hospital Association* **37**, 577-581

Mellanby, R. J., Villiers, E. & Herrtage, M. E. (2002) Canine pleural and mediastinal effusions: a retrospective study of 81 cases. *Journal of Small Animal Practice* **43**, 447-451

Moores, A. L., Halfacree, Z. J., Baines, S. J. & Lipscomb, V. J. (2007) Indications, outcomes and complications following lateral thoracotomy in dogs and cats. *Journal of Small Animal Practice* **48**, 695-698

Orton, E. C. (2003) Thoracic wall. In: Textbook of Small Animal Surgery. 3rd edn. Eds D. Slatter. W. B. Saunders, Philadelphia, PA, USA. pp 374-375

Pascoe, P. J. & Dyson, D. H. (1993) Analgesia after lateral thoracotomy in dogs. Epidural morphine versus intercostal bupivacaine. *Veterinary Surgery* **22**, 141-147

Potter, L. & Hendrickson, D. A. (1999) Therapeutic video-assisted thoracicsurgery. In: Veterinary Endosurgery. Eds L. J. Freeman. C. V. Mosby, St Louis, MO, USA. pp 167-191

Radlinsky, M. G., Mason, D. E., Biller, D. S. & Olsen, D. (2002) Thoracoscopic visualization and ligation of the thoracic duct in dogs. *Veterinary Surgery* **31**, 138-146

Ringwald, R. J. & Birchard, S. J. (1989) Complications of median sternotomy in the dog and literature review. *Journal of the American Animal Hospital Association* **25**, 430-434

Rooney, M. B. & Monnet, E. (2002) Medical and surgical treatment of pyothorax in dogs: 26 cases (1991-2001). *Journal of the American Veterinary Medical Association* **221**, 86-92

Rooney, M. B., Mehl, M. & Monnet, E. (2004) Intercostal thoracotomy closure: transcostal suture as a less painful alternative to circumcostal suture placement. *Veterinary Surgery* **33**, 209-213

Schultz, R. M. & Zwingenberger, A. (2008) Radiographic, computed tomographic, and ultrasonographic findings with migrating intrathoracic grass awns in dogs and cats. *Veterinary Radiology & Ultrasound* **49**, 249-255

Scott, J. A. & Macintire, D. K. (2003b) Canine pyothorax: clinical presentation, diagnosis and treatment. *Compendium on Continuing Education for the Practicing Veterinarian* **25**, 180-194

Walsh, P. J., Remedios, A. M., Ferguson, J. F., Walker, D. D., Cantwell, S. & Duke, T. (1999) Thoracoscopic versus open partial pericardectomy in dogs: comparison of postoperative pain and morbidity. *Veterinary Surgery* **28**, 472-479

Walton, R. S. (1999) Thoracoscopy. In: Small Animal Endoscopy. 2nd edn. Eds T. R. Tams. C. V. Mosby, St. Louis, MO, USA. pp 471-488

Walton, R. S. (2001) Video-assisted thoracoscopy. *Veterinary Clinics of North America Small Animal Practice* **31**, 729-759

Zaal, M. D., Kierpensteijn, J. & Peeters, M. (1997) Thoracoscopic approaches in the dog. *Veterinary Quarterly* **19**