# EL SINDROME BRAQUICEFALICO

**Manuel Jiménez Peláez, DVM, MRCVS, Diplomate ECVS**
Davies Veterinary Specialists, Higham Gobion, Hertfordshire, UK
mjp@vetspecialists.co.uk

## 1. Consideraciones generales:

La obstrucción de las vías aéreas superiores del síndrome braquicefálico (SB) presenta tres componentes esenciales:

1. Componente nasal: estenosis de narinas (estrechez de los orificios nasales) y estenosis nasal debido a los pliegues mucosos nasales exuberantes.
2. Componente naso/oro-faríngeo: excesivo espesor y longitud del paladar blando e inflación de la región secundaria a los esfuerzos inspiratorios permanentes y a las regurgitaciones. Pliegues exuberantes de la mucosa y macroglosia.
3. Componente laríngeo: irritación por la vibración y aspiración del paladar blando en la glotis, eversión de los ventrículos/sáculos laríngeos, hundimiento-depresión y debilidad-flacidez congénita laríngea y colapso laríngeo (componentes secundarios mayoritariamente).

Estos componentes provocan un aumento de la resistencia al paso del aire inspirado y por tanto una disminución de su débito. Suelen observarse síntomas digestivos y respiratorios al mismo tiempo. La presencia de una hiperplasia del paladar blando es la anomalía que se encuentra con mayor frecuencia, prácticamente en el 100% de los braquicéfalos.

Los síntomas respiratorios observados frecuentemente son: ronquidos (tanto diurnos como nocturnos), ruidos inspiratorios, dificultad respiratoria e intolerancia al esfuerzo y al calor, cianosis pudiendo ir hasta el sincope. Los síntomas digestivos que se observan con mayor frecuencia son: vómitos de comida no digerida o de baba-espuma (después de un esfuerzo) y regurgitaciones.

El clínico de pequeños animales tiene un papel fundamental concienciando al propietario de este tipo de razas. Hay que luchar contra el tópico de: “es normal que mi perro ronque y tenga dificultad respiratoria al menor esfuerzo, ya que es un braquicéfalo”. La precocidad en el diagnostico y en el tratamiento quirúrgico son las claves para manejar con éxito esta afección evolutiva.

Frente un SB, es indispensable establecer un protocolo diagnostico sistemático y completo para investigar todos los componentes del síndrome y otras anomalías asociadas, como una hernia de hiato, esofagitis y gastritis crónica, una insuficiencia cardiaca derecha, bronconeumonía, etc. Es por ello que un chequeo completo (endoscopia respiratoria y digestiva, radiografías torácicas) permite optimizar la elección terapéutica y afinar el pronóstico. La hipoplasia traqueal es otra de las anomalías que pueden observarse en perros braquicéfalos (bulldog inglés principalmente). En la mayoría de los casos es una hipoplasia “patológica” pero no o poco sintomática (contrariamente a lo que a veces se cree) y los síntomas respiratorios suelen ser secundarios a otra/s de las anomalía/s presentes en el SB y no a la presencia de esta hipoplasia traqueal.

El pronóstico después del tratamiento quirúrgico más habitual (narinas y paladar blando +/- escisión ventrículos laríngeos evertidos) es bueno a excelente en los jóvenes sin colapso laríngeo avanzado asociado, y reservado si son mayores y si existen lesiones secundarias o concomitantes (colapso laríngeo avanzado, bronconeumonía). Es por ello que la cirugía debe realizarse cuanto antes (incluso a los 6 meses de edad) y estar sistemáticamente asociada a un tratamiento medicamentoso cuando existe concomitancia de síntomas digestivos (omeprazol, etc.). Cuanto antes se realice la cirugía, menos y menores lesiones secundarias a la obstrucción respiratoria crónica estarán presentes (como la eversión de sáculos laríngeos, colapso laríngeo avanzado) y mejor será el pronóstico.

Hay que tener presente que es un síndrome evolutivo que irá agravándose a medida que pasa el tiempo, hay que ser reactivos y actuar cuanto antes. Debemos explicarle al propietario las implicaciones y repercusiones que éstas pueden acarrear en un futuro, sino son corregidas a tiempo.

**2. Tratamiento quirúrgico:**

La cirugía de primera elección es corregir el paladar blando y las narinas en el mismo tiempo anestésico. En la mayoría de los casos, esta doble intervención es suficiente para mejorar los síntomas y la calidad de vida del perro. La escisión de los ventrículos laríngeos, cuando una eversión moderada o severa está presente, también se debe realizar en primera intención. Cuando las anomalías laríngeas presentes son severas y no se obtiene la mejoría esperada con la primera cirugía, procedemos a intentar corregirlas en un segundo tiempo quirúrgico.

Los perros que sufren del SB presentan un riesgo anestésico elevado, sobre todo en el momento de recuperación de la anestesia. Deben ser vigilados de manera intensiva durante al menos las primeras 24 horas postoperatorias.

- Algunas pautas para la anestesia:

- Premedicación que usamos (intramuscular): acepromacina (0,02-0,05 mg/kg si no hay anomalía cardiaca), dexametasona (0,2 mg/kg), metoclopramida (0,5 mg/kg) y morfina (0,1-0,2 mg/kg) o metadona (0.3 mg/kg).
- Oxigenación preoperatoria
- Inducción intravenosa rápida: profofol (4-6 mg/kg), precedido de una benzodeazepina si no se ha realizado la acepromacina.
- Intubación oro-traqueal + isoflurano + oxígeno.
- Extubación lo más tardía posible.
- Despertarlo con una sonda naso-traqueal de oxígeno (dejarla 24-48h) si el animal la tolera bien.

- Posicionamiento del animal:

Decúbito esternal, mesa inclinada (cabeza en alto), boca bloqueada en apertura máxima (con la ayuda de esparadrapo), lengua sacada completamente y fijada al exterior con esparadrapo. Gasa en el fondo de la garganta, detrás del paladar blando.

2. a. Palatoplastia clásica (estafilectomía):

Hasta hace pocos años era la técnica más utilizada, hoy en día en ciertos centros va dando paso a la palatoplastia modificada (Folded flap palatoplasty) por Gilles Dupré (Dupré y Findji, 2004; Dupré y coll. 2005).

La palatoplastia clásica tiene como objetivo seccionar el borde libre (exceso de longitud) del paladar blando. La sección suele realizarse con tijeras de Metzembaum (también puede usarse el bisturí eléctrico o un láser), traccionando la parte libre del paladar blando con una sutura de tracción o una pinza de Allis por ejemplo. Se va seccionando poco a poco, y suturando a medida (monofilamento, reabsorbible 3-0 o con más frecuencia 4-0 UPS, aguja de sección redonda) la mucosa naso-palatina a la mucosa oro-palatina. Las hemorragias y el edema laríngeo son frecuentes, así como la necesidad en postoperatorio de una traqueotomía temporal. Esta técnica solo corrige el exceso de longitud del paladar blando, sin tener ningún cambio significativo sobre la obstrucción nasofaríngea ni orofaríngea.

2. a. Palatoplastia modificada (FFP: Folded Flap Palatoplasty; mirar articulo original adjunto):

Es la técnica que usamos desde hace unos 8 años, con muy buenos resultados clínicos post-operatorios inmediatos y a largo plazo (Findji y Dupré, 2008). Puede realizarse con bisturí eléctrico, láser diodo o láser de $CO_2$. Según nuestra experiencia el buen uso del bisturí eléctrico no provoca edema, contrariamente al pensamiento de otros autores. Los mejores resultados se han obtenidos con el láser $CO_2$ (Dunie-Merigot y coll. 2008).

El objetivo de esta técnica es, no solo de corregir el exceso de longitud, sino también el exceso de espesor del paladar blando. La existencia de este exceso de espesor del paladar blando ya ha sido evocada en estudios precedentes.

El límite dorsal de la sección (en arco) se sitúa ligeramente por encima de las amígdalas. A esta altura y casi en dirección perpendicular al paladar blando, se realiza la sección del límite dorsal en profundidad incluyendo los músculos palatinos y atravesando a este nivel el paladar blando. Luego se termina la sección de ambos lados, caudo-lateralmente, respetando y pasando paralelamente a las amígdalas. La hemostasia debe ser más intencionada en los ángulos caudo-dorso-laterales de la sección (arterias palatinas menores). Realizar una sutura entre la mucosa naso-faríngea que la traccionamos hacia delante y la mucosa oro-faríngea (2 medias suturas continuas, monofilamento reabsorbible, aguja sección redonda, 4-0 UPS).

Esta técnica que se acaba de describir es una variante de la palatoplastia modificada original. En la original, (Dupré y Findji, 2004; Dupré y coll. 2005) también se retiran los músculos palatinos pero no se atraviesa la mucosa naso-faríngea del paladar blando (se le quita espesor sin atravesar la mucosa naso-faringea) y se desplaza hacia delante un colgajo o “flap” de la mucosa del paladar blando (al que se le ha retirado el espesor previamente), luego se sutura este “flap” de mucosa cranealmente al borde libre dorsal de la incisión utilizando la misma técnica que anteriormente. El objetivo de la variación de la palatoplastia modificada, es de acortar al máximo este colgajo o “flap” mucoso.

Con ambas modificadas, los resultados son realmente alentadores: menos edema, menos hemorragia, casi ausencia de traqueotomías (5% contra 27.9 % de otros estudios con la técnica clásica), despertar de anestesia con menor riesgo, etc.

De todas formas, la sonda naso traqueal de oxígeno también de deja 24-48h y una vigilancia intensiva postoperatoria sigue de rigor. Aunque con esta técnica el paladar se acorta más de lo recomendado, con el riesgo consecuente de paso de alimentos hacia nasofaringe, ya que el paladar evita esto tanto activamente como pasivamente, es una complicación con una incidencia mínima, prácticamente nula.

2. c. Ventriculectomía:

Los ventrículos o sáculos laríngeos están situados justo rostralmente a las cuerdas vocales. Para realizar su escisión el animal sigue situado como precedentemente. La extremidad del ventrículo se tracciona con una pinza de Allis o fórceps curvos largos, y su base es seccionada con unas tijeras de Metzembaum. El uso de instrumentos finos, largos y curvos facilita la maniobra. La hemostasia se realiza simplemente por compresión de la base del ventrículo con una gasa húmeda por ejemplo. El procedimiento se repite con el ventrículo contra lateral.

La extremidad de uno (o ambos) de los cartílagos cuneiformes, puede ser requerida en asociación a la ventriculectomía en casos de colapso laríngeo de estado 2. Cuando se realiza esta cirugía, el riesgo de edema y sangrado postoperatorio aumenta; una traqueotomía temporal puede necesitarse.

La pauta que yo sigo es solo realizar una ventriculectomía cuando la eversión es completa, crónica y la obstrucción provocada por la eversión de los ventrículos es de moderada a severa (≥ 1/3). En algunos casos más severos (colapso laríngeo de estado 2: eversión de los ventrículos y colapso de los cartílagos cuneiformes, muy típico en los perros carlinos), es necesario realizar la resección (con tijera de Metzembaum o laser $CO_2$) de la extremidad libre de uno o ambos de los cartílagos cuneiformes colapsados. Cuando la eversión es menor o incompleta, tengo tendencia a no retirarlos en primera intención en el momento de tratar el paladar blando y las narinas. Siempre y cuando la eversión no sea crónica, el hecho de corregir los componentes primarios (paladar y narinas), suele ser suficiente para mejorar la eversión de ventrículos, irán tomando su sitio poco a poco al recuperar el perro una presión inspiratoria casi fisiológica.

2. d. Rinoplastia:

Para realizar la rinoplastia en cuña, situamos al animal con la boca cerrada, cabeza apoyada en la mesa y mordiendo un paquete de 3-4 gasas.

Se usa una hoja de bisturí del n° 11 nueva para cada narina. Nos ayudamos con una pinza de disección tipo Adson o Adson-Braun para poner la narina en tracción y realizar las secciones con precisión. Se realizan 2 incisiones que se unen en un punto dorsal, la primera paralela al lado interno y la segunda lateralmente, formando una cuña con la base ventral. Ambas secciones deben ser profundas, hasta el cartílago alar de la narina. Sangra bastante pero no es necesario realizar hemostasia, al poner los puntos la hemorragia se para. Se suturan borde a borde los lados medial y lateral restantes de la narina, con puntos simples (reabsorbibles o no, aguja triangular, monofilamento, 4-0 USP). Poner especial atención a la simetría de ambas narinas.

2. e. Turbinectomía:

Es una técnica publicada por Oechtering en 2006, cuyo objetivo es corregir la estenosis interna de la cavidad nasal, realizada con un láser diodo guiado con un fibroscopio.

Un estudio realizado con 50 braquicéfalos con insuficiencia respiratoria severa, ha revelado la existencia, en el 50% de los casos, de una estenosis de coanas y del meato naso-faríngeo, por una hipertrofia de la mucosa de los cornetes nasales ventral y medio. Esta técnica procede a la escisión de estos repliegues exuberantes de la mucosa nasal y ha dado muy buenos resultados asociándola a una rinoplastia y a una palatoplastia.

**3. Pronóstico:**

Buen pronostico en los animales jóvenes y/o sin lesiones secundarias importantes como el colapso laríngeo, con una mejoría neta y durable de los síntomas respiratorios (88%-97,5%) y digestivos (80%).

Las complicaciones postoperatorias son frecuentes: ronquidos (73,9%) y disnea (21,7%) persistentes en fase postoperatoria, traqueotomía (casos de disnea preoperatoria severa y/o colapso laríngeo), mortalidad (3,6% con la modificada hasta el 14.8 % en los estudios publicados con la técnica convencional.

Cuando un colapso laríngeo avanzado está presente en un animal con un SB, el pronóstico es reservado. La opción terapéutica, por defecto, la menos mala e incierta, es asociar la palatoplastia la lateralización de uno de los cartílagos aritenoides.

## Referencias y lectura recomendada:


EVANS, H.(ed.):Miller's anatomy of the dog, 3rd ed., Saunders, Philadelphia, 1993.

DAVIDSON, E.B., DAVIS, M.S., CAMPBELL, G.A., WILLIAM-SON, K.K., PAYTON, M.E., HEALEY, T.S., BARTELS, K.E.(2001):Evaluation of carbon dioxide laser and conventionalincisional techniques for resection of soft palates in brachycephalic dogs. J.Am.Vet.Med.Assoc.219, 776-781.

DUPRÉ, G., FINDJI, L.(2004):La palatoplastie modifiée chez lechien. Le Nouveau Praticien Vétérinaire.20, 553-556.

DUNIE-MERIGOT A., PONCET C., BOUVY B. (2010). Comparative use of CO2 laser, diode laser and monopolar electrocautery for resection of the soft palate in dogs with brachycephalic airway obstructive syndrome: 60 cases. Vet Record ,vol. 167, pp. 700-704.

FINDJI, L., DUPRÉ, G. (2008): Folded flap palatoplasty for treatment of elongated soft palates in 55 dogs. Wien. Tierärztl. Mschr. 95, 56–63.

HARVEY, C.E., VENKER-VON HAAGAN, A.(1975):Surgical management of pharyngeal and laryngeal airway obstruction in the dog.Vet.Clin.North Am.5, 515-535.

HENDRICKS, J.C.(1992):Brachycephalic airway syndrome. Vet.Clin.North Am.Small Anim.Pract.22, 1145-1153.

KOCH D.A., ARNOLD S., HUBLER M., MONTALVON P. (2003). Brachycephalic syndrome in dogs. Compend. Contin. Educ. Pract. Vet. 25(1), 48-55.

LORINSON, D., BRIGHT, R.M., WHITE, R.A.S.(1997):Brachycephalic airway obstruction syndrome - a review of 118 cases. Canine Pract.22, 18-21.

NELISSEN P and WHITE RAS (2012). Arytenoid Lateralization for Management of Combined Laryngeal Paralysis and Laryngeal Collapse in Small Dogs. Vet Surgery Volume 41, Issue 2, pages 261–265.

NOTHRUP N.C. et coll. Retrospective study of orthovoltage radiation therapy for nasal tumors in 42 dogs. J. Vet. Inter. med., 2001, 15: 183-189.

OECHTERING G.U., HUEBER J., KIEFER I., NOELLER C. (2006). Laser assisted turbinectomy (LATE)– A novel approach to brachycephalic airway syndrome. 2006 ECVS annual meeting Dublin, Ireland.

SLATTER DH (eds): Textbook of small animal surgery (ed 3), Philadelphia, PA, Saunders, 2003.

TOBIAS KM, JOHNSTON SA (1st ed): Textbook of Veterinary Surgery: Small Animal. Saunders, 2012.

Vet. Med. Austria / Wien. Tierärztl. Mschr. **95** (2008), 56 - 63

From the Centre Hospitalier Vétérinaire Frégis, Arcueil, France

# Folded flap palatoplasty for treatment of elongated soft palates in 55 dogs

L. FINDJI and G. DUPRÉ

received April 10, 2007
accepted for publication September 10, 2007

**Keywords**: brachycephalic airway syndrome, elongated soft palate, soft palate hyperplasia, folded flap palatoplasty.

**Summary**

It was the aim of the present study to evaluate the safety and efficacy of the folded flap palatoplasty (FFP), a new surgical technique addressing all components of the respiratory obstruction caused by elongated soft palates, and to evaluate the clinical outcomes associated with it.

Medical records (2004-2005) of all dogs which underwent a FFP were reviewed and included in the study. Recorded information included breed, gender, age, body mass, duration of hospitalisation, and presence or absence of postoperative tracheostomy. Respiratory grading scores (1-3) were used to record the severity of the disease, before and after surgery, and at a minimum follow-up time of 180 days by detailed telephone interviews with the owners.

No intraoperative complications were encountered. A temporary tracheostomy was performed in 6 cases (10.9 %). 2 dogs died postoperatively from tracheostomy complications and unknown cause after unremarkable recovery, respectively. Follow-up (379 ± 142 days) could be obtained for 40 dogs. 39 dogs (97.5 %) showed improvement of respiratory clinical signs after surgery. Improvement of respiratory clinical signs was observed within 15 days after surgery in 85 % of the cases.

The FFP can be recommended as a safe and efficient technique, particularly valuable for excessively thick elongated soft palates.

Abbreviations: BAS = brachycephalic airway syndrome; CT = computed tomodensitometry; ESP = elongated soft palate; FFP = folded flap palatoplasty; MRI = magnetic resonance imaging

**Schlüsselwörter**: brachyzephales Syndrom, verlängertes Gaumensegel, Hyperplasie des weichen Gaumens, Faltlappenplastik.

**Zusammenfassung**

**Einsatz einer Faltlappenplastik des weichen Gaumens zur Behandlung des verlängerten Gaumensegels bei 55 Hunden**

Im Rahmen dieser Studie wurden die Sicherheit und Effizienz einer Faltlappenplastik (FFP) untersucht und eine neue chirurgische Technik beschrieben, welche alle Komponenten einer Atemwegsobstruktion, verursacht durch ein verlängertes Gaumensegel, berücksichtigt. Das daraus resultierende Ergebnis wurde evaluiert.

Es wurden die Krankengeschichten (2004-2005) von allen Hunden, die einer FFP unterzogen worden waren, überprüft und in diese Studie aufgenommen. Unter den aufgezeichneten Daten befanden sich Rasse, Geschlecht, Alter, Körpermasse, Dauer des Spitalsaufenthaltes und das Setzen/Nicht-Setzen eines Tracheotomietubus. Ein Benotungsschema für die Atmung wurde verwendet (1-3), um den Schweregrad der Erkrankung vor und nach der Operation erfassen zu können. Die minimale Zeit der Nachkontrolle der Fälle betrug 180 Tage, sie erfolgte in Form detaillierter Telephonbefragungen der Besitzer.

Es wurden keine intraoperativen Komplikationen beschrieben. Eine temporäre Tracheostomie wurde in 6 Fällen durchgeführt (10,9 %). 2 Hunde starben postoperativ: ein Hund durch eine Tracheostomiekomplikation, ein Hund aus unbekannter Ursache, nach einer unauffälligen Aufwachphase aus der Narkose. Ein Follow-up der operierten Hunde konnte bei 40 Hunden erzielt werden (379±142 Tage). 39 Hunde (97,5 %) zeigten eine klinische Verbesserung der Atmung nach erfolgtem chirurgischem Eingriff. In 85 % der Fälle war diese Besserung innerhalb von 15 Tagen postoperativ zu beobachten.

Somit kann die FFP als eine sichere und effiziente Methode empfohlen werden, welche vor allem bei übermäßig verdicktem Gaumensegel wertvoll ist.

## Introduction

Elongated soft palate (ESP) is part of brachycephalic airway syndrome (BAS), a widespread condition in brachycephalic dogs. Although recent studies have demonstrated the high incidence of BAS-associated digestive lesions and the benefits resulting from their medical treatment regarding outcome and prognosis (PONCET et al., 2005, 2006), surgical relief of the upper airway obstruction still constitutes the cornerstone of its treatment.

Up to 100 % of brachycephalic dogs are reported to suffer from ESP (WYKES, 1991; PONCET et al., 2006), which can cause laryngeal obstruction due to aspiration to the rima glottidis during inspiration. Elongated soft palates also commonly demonstrate excessive thickness, which is considered to cause narrowing and obstruction of the naso-

and oro-pharynx, further contributing to respiratory compromise in affected individuals. Conventional surgical techniques used for correction of ESP consist of its shortening by resection of its caudal aspect (staphylectomy). These techniques address the laryngeal obstruction but are unlikely to achieve significant relief of the nasopharyngeal and oropharyngeal obstructions (DUPRÉ and FINDJI, 2004). Recently, a new surgical technique has been devised to address and relieve all the components of airway obstruction associated with ESP (DUPRÉ and FINDJI, 2004; DUPRÉ et al., 2005). The aim of this study was to assess whether FFP is suitable for treatment of ESP, and whether it is associated with good results and few complications.

# Material and methods

### Inclusion criteria

Medical records of all the dogs which had a folded flap palatoplasty (FFP) between March 2004 and October 2005 were reviewed. During this period, FFP was used exclusively for treating ESP. Recorded information included breed, age, body mass, birth date, duration of hospitalisation and the requirement for temporary tracheostomy in the postoperative period. Whenever possible, detailed telephone interviews with owners, using a consistent questionnaire, were obtained with a minimum follow-up of 180 days.

### Clinical assessment and anaesthesia

Upon admission, clinical history was obtained from the owners. The severity of respiratory clinical signs was then graded by the admitting clinician using a 1 to 3 score, according to the scale established by PONCET et al. (2005; Tab. 1). The degree of nare stenosis was subjectively evaluated.

Food and water were withheld for a minimum of 15 hours before anaesthesia. Premedication included 0.05 mg/kg acepromazine (Calmivet®; Vétoquinol, Lure, France), 0.2 mg/kg dexamethasone (Dexadreson®; Intervet, Angers, France), 0.5 mg/kg metoclopramide (Primperid®; Sanofi, Paris, France) and 0.01 mg/kg glycopyrrolate (Robinul®; Vétoquinol), all administered intramuscularly. General anaesthesia was induced with intravenous thiopenthal (5-10 mg/kg i.v.; Nesdonal®; Merial, Lyon, France) or propofol (3-5 mg/kg i.v.; Rapinovet®; Schering-Plough, Levallois Perret, France) and maintained with isoflurane (Aerrane®; Baxter, Maurepas, France), in 100 % oxygen.

On induction, direct visual or endoscopic evaluation of the upper airway was carried out by the surgeon. The soft palate was examined with regards to its length and thickness by manipulation and palpation with forceps. The tonsils, the pharynx and the larynx were subjectively evaluated.

### Surgical procedure

The dog was placed in ventral recumbency. The head was restrained with the mouth kept open. The tongue was pulled rostrally and fixed with tape to allow better exposure of the oropharynx (Fig. 1). After surgical preparation of the oral cavity, the caudal edge of the soft palate was grasped with forceps or traction sutures and retracted rostrally, until the caudal opening of the nasopharynx could be visualised. The retracted caudal edge was then applied on the ventral mucosa of the soft palate and the point at which the contact was made (usually 1 or 2 cm caudal to the palatine process of the palatine bone) was marked with an electrocautery cut. The ventral mucosa of the soft palate was then incised in a trapezoidal shape from this mark rostrally to the free edge of the soft palate caudally. Laterally, the sides of the trapezoid passed just medially to the tonsils (Fig. 2). The soft tissues under the cut portion of the soft palate were excised together with the ventral mucosa of the soft palate, the palatinus muscles and part of the levator veli palatini muscle (Fig. 3). The dissection ended when this portion of the soft palate was reduced to the nasopharyngeal mucosa and submucosa. The caudal edge of the soft palate was retracted rostrally to the rostral edge of the trapezoidal incision (Fig. 4). The soft palate was then sutured folded on itself with interrupted monofilament absorbable sutures (glycomer 631, Biosyn®; Tyco, Elancourt, France) (Fig. 5).

The mouth was then freed and closed. When stenotic nares were diagnosed, dogs subsequently underwent a vertical wedge resection rhinoplasty (MONNET, 2003) during the same surgical procedure. At the time of the study, non absorbable monofilament sutures were still used for rhinoplasty, as previous attempts to use absorbable suture material resulted in more inflammatory wounds and poorer cosmetic results.

### Postoperative care

After surgery, the mouth and pharynx were washed to remove debris, clots and saliva, and a nasotracheal tube (Pediatric feeding tubes 40 cm, 6 to 10 FG, Salva, Unomedical, Birkerød, Danemark) was placed for postoperative oxygen therapy (50 ml/kg/min). In cases considered at risk from life-threatening pharyngeal or laryngeal obstruction because of excessive secretions, vomiting or laryngeal collapse, a temporary tracheostomy tube was placed (Jackson double-lumen tracheostomy tube [Tracheostomy tube Rüschelit Biesalski, 7 and 8 mm, Rüsch, Kernen, Germany]). Additional postoperative care consisted of appropriate administration of dexamethasone, metoclopramide, or glycopyrrolate and intra-oral suction, chest percussion and tracheostomy tube care if needed. Dogs were discharged from hospital when no specific nursing care had been necessary for at least 12 hours. Duration of hospitalisation was recorded.

### Follow-up

Dogs which underwent a rhinoplasty were re-evaluated at the time of suture removal and an interview with the owners was conducted with a minimum of 6 month follow-up, using a consistent questionnaire (Tab. 2), for all dogs.

### Statistical analysis

Categorical data (e.g. breed or gender) are reported as frequencies and percentages. Continuous data (e.g. age at presentation or hospitalisation duration) are reported as mean ± SD. Chi square analyses were used to study the distribution of males and females in the studied population, and to evaluate the significance of the changes in the repartition of the animals between grades before and after surgery. t-tests were used to evaluate whether the duration of hospitalisation was different for animals which underwent a tracheostomy compared to those which did not. The

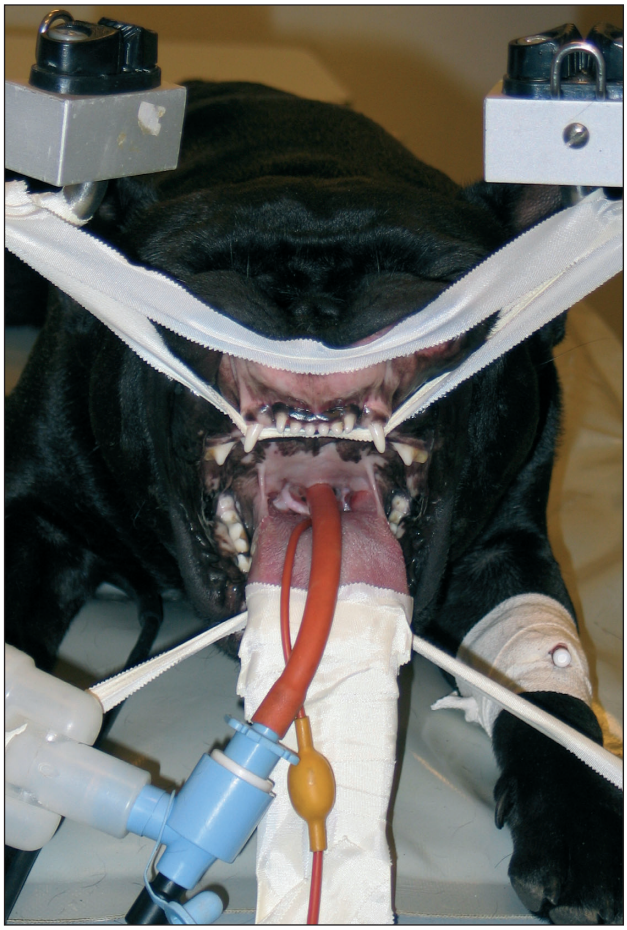

**Fig. 1:** Positioning of the dog for surgery

use of t-tests was possible after a Kolmogorov-Smirnov test indicated no significant deviation from normal distribution. For every statistical test, significance was established at $p<0.05$. All analyses were performed with commercial statistical software (SPSS for Windows 14.0, SPSS Inc., Chicago, IL).

# Results

### Epidemiological data

55 dogs underwent a FFP between March 2004 and October 2005 and were included in this study. 45 dogs were males (81.8 %) and 10 were females (18.2 %). Significantly more males were affected ($p<0.001$). Age at the time of surgery ranged from 6 to 105 months (mean 39 ± 22.6 months, median 34.6 months). 8 different breeds were represented: French bulldog (n=32, 58.2 %), Pug (n=8, 14.5 %), English bulldog (n=7, 12.7 %), Boxer (n=3, 5.5 %), King Charles Spaniel (n=2, 3.6 %), Norwich terrier (n=1, 1.8 %), Sharpei (n=1, 1.8 %) and Shi Tzu (n=1, 1.8 %). Body mass at the time of surgery ranged from 6.5 to 46 kg (mean 14.9 ± 7.9 kg, median 12.3 kg).

### Clinical findings

Grading was recorded for dogs whose follow-up could be obtained (Fig. 6). 3 dogs had undergone prior conventional staphylectomy 8 months, 1 and 4 years before surgery, respectively, but showed clinical signs of nasopharyngeal and oropharyngeal obstructions due to excessive thickness of the remaining soft palate that necessitated reintervention.

Stenotic nares were diagnosed in 50 dogs (90.9 %). One dog had already been treated surgically, and 4 dogs had normal nares.

One dog suffered from laryngeal paresis and laryngeal saccule eversion. One dog had undergone prior lateralization of left arytenoid cartilage 3 months before surgery.

### Surgical procedure

All dogs underwent a FFP. No intraoperative complications were encountered. Rhinoplasty was performed in 50 dogs. In one dog, concomitant severe laryngeal collapse and laryngeal oedema required arytenoid lateralization and temporary tracheostomy in the early postoperative period. No other surgical procedures addressing the respiratory tract were performed concomitantly.

### Postoperative care and treatment

A temporary tracheostomy was performed in 6 cases (10.9 %). These 6 dogs were suffering from grade 3 respiratory clinical signs before surgery. All dogs had oxygen therapy provided through either the tracheostomy or a nasotracheal tube. Mean duration of hospitalisation was 1.6 ± 1.1 days (range 1 to 6 days). It was 1.3 ± 0.5 days (range 1 to 2 days) for dogs which did not have a tracheostomy performed and 4.4 ± 1.1 days (range 3 to 6 days) for dogs which did, which was significantly longer ($p=0.003$).

2 dogs died perioperatively (3.6 %). One dog had had a tracheostomy and died 16 hours after surgery from respiratory distress caused by excessive tracheal secretions, despite close tracheal tube surveillance. The other dog died from cardiovascular collapse of undetermined origin, 12 hours after surgery, after unremarkable recovery. Postmortem examinations of these dogs were declined by the owners.

All other 53 dogs (96.4 %) were discharged from hospital without complication.

### Follow-up

A minimum of 6 month follow-up could be obtained for 40 dogs. 13 dogs were lost to follow-up. Follow-up ranged from 183 to 715 days (379 ± 142 days).

The evolution of respiratory grades between preoperative and postoperative periods and follow-up are illustrated in Fig. 6. Respiratory grades were improved significantly between preoperative and postoperative periods ($p<0.001$), and between preoperative and follow-up periods ($p<0.001$). On the contrary, no significant difference was found in respiratory grades between postoperative and follow-up periods ($p=0.497$). The times from surgery to improvement of respiratory clinical signs are shown in Fig. 7.

No pharyngonasal regurgitations or nasal discharge were reported, either at time of suture removal or at follow-up.

# Discussion

Although seldom reported in the literature, excessively thick ESP has previously been mentioned (AMIS and KURPERSHOEK, 1986; HENDRICKS et al., 1987). Its

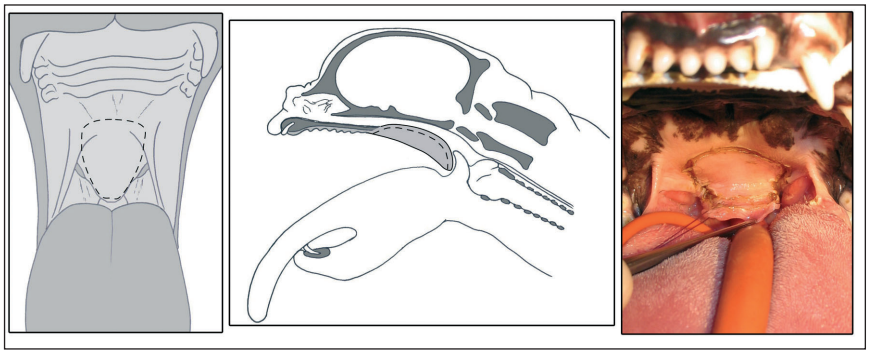

**Fig. 2:** Incision line (frontal, sagittal and intraoperative views)

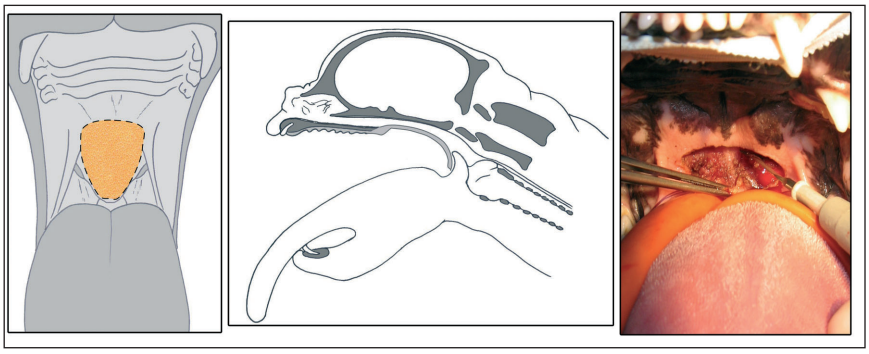

**Fig. 3:** End of dissection (frontal, sagittal and intraoperative views)

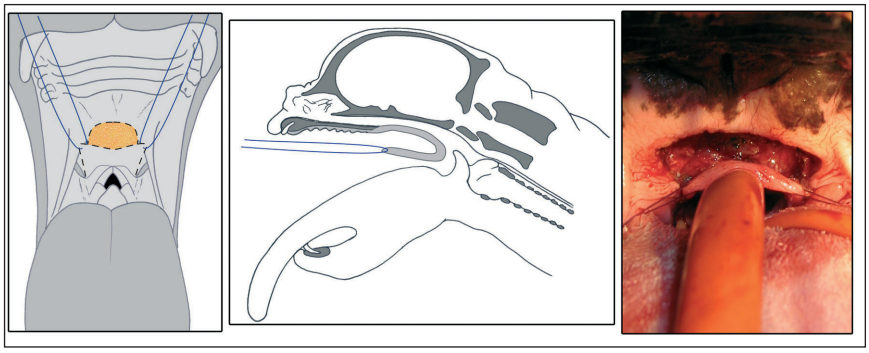

**Fig. 4:** Soft palate folding (frontal, sagittal and intraoperative views)

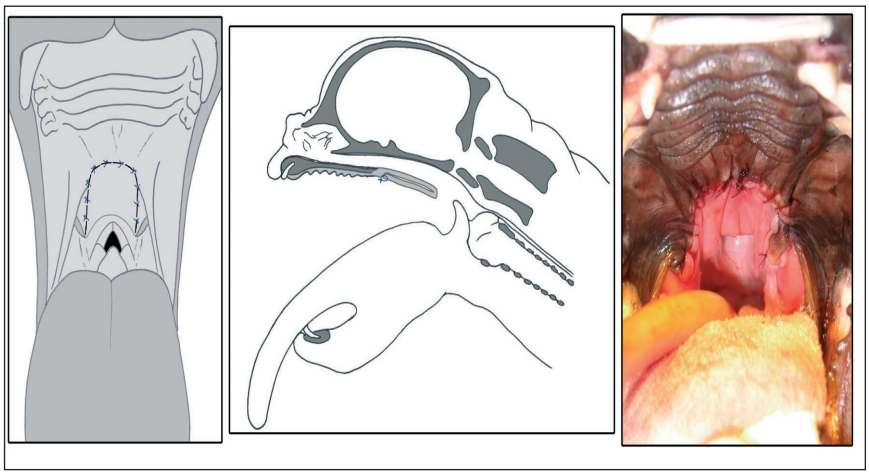

**Fig. 5:** Sutured flap (frontal, sagittal and intraoperative views)

incidence seems to vary widely from one breed to another, but anatomical studies which could confirm this observation are lacking. In the absence of such studies or precise normal ranges, the diagnosis of excessively thick ESP remains subjective and can be made by ways of direct examination and palpation of the soft palate, or lateral radiographs (Fig. 8 and 9), CT scan or MRI of the pharyngeal area. Ideally, imaging should be done without oral intubation, which is not without risks in brachycephalic dogs. It can also be made retrospectively, after surgical excision, by direct examination of the excised tissues. In this preliminary retrospective study, the thickness of the soft palate in pre and postoperative periods was not recorded. The assessment of the oro- and nasopharyngeal obstructions would however have been of greater relevance but would have required advanced diagnostic imaging means (CT scan or MRI) and was not technically achievable in our hospital. In the absence of advanced

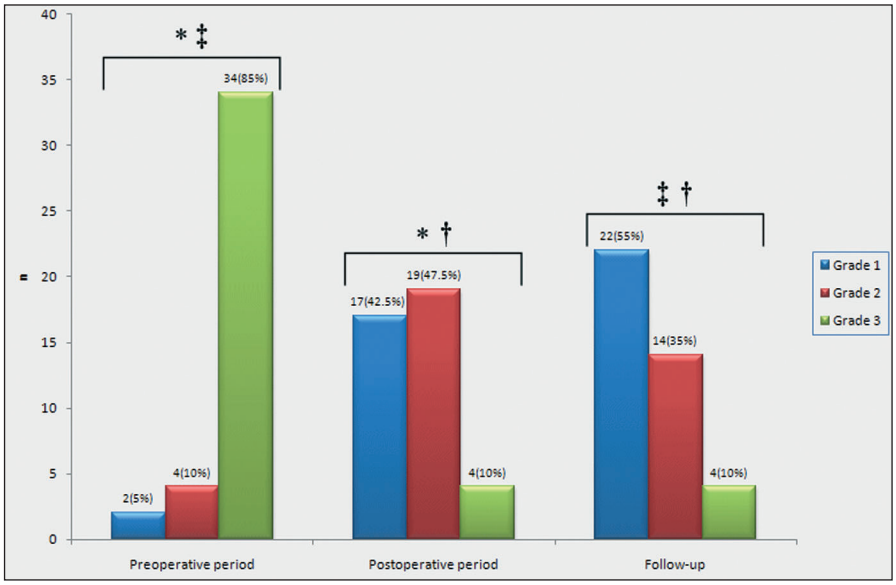


**Fig. 6:** Distribution of respiratory grades in preoperative and postoperative periods, and at follow-up (*, ‡: preoperative/postoperative and preoperative/follow up distributions are significantly different, p<0.001; †: postoperative/follow-up distributions are not significantly different, p=0.497).

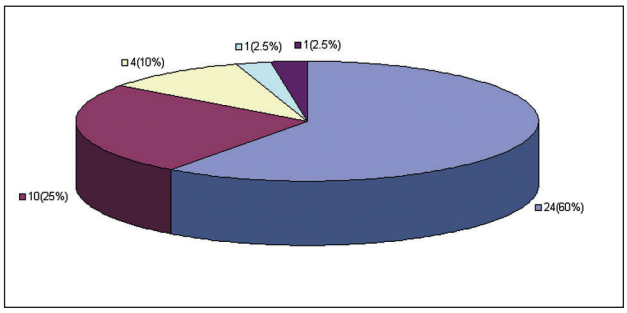


**Fig. 7:** Time from surgery to improvement of respiratory signs

diagnostic imaging, the most accurate assessment of the preoperative soft palate thickness is obtained retrospectively, after the FFP has been performed, and the soft palate has been dissected and excised (Fig. 10). Over the study period, the FFP was used exclusively, regardless of the preoperative subjective assessment of the soft palate thickness, which is therefore facultative. Further studies including pre- and postoperative objective measurements of the oro- and nasopharyngeal volumes by means of CT scan or MRI would, however, be valuable.

The FFP thins the soft palate by excising most of the connective and muscular tissues responsible for its excessive thickness, and thus relieves oropharyngeal and nasopharyngeal obstructions (DUPRÉ and FINDJI, 2004; DUPRÉ et al., 2005). This study is to date the first report on the outcome of a series of dog undergoing this surgical procedure.

Previously described surgical techniques aim at shortening the ESP (HARVEY, 1982b; CLARK and SINIBALDI, 1994) to relieve the laryngeal obstruction it causes. The FFP achieves the same effect as it shortens the soft palate by folding it on itself. However, with the FFP, the ESP is left shorter than usually recommended (MONNET, 2003) to achieve thinning of the soft palate on its entire length; the nasopharyngeal opening is most often directly visible in the mouth after the procedure (Fig. 5). Excessive shortening of ESPs is thought to expose to pharyngonasal regurgitations (HARVEY, 1982b; BRIGHT and WHEATON, 1983; WYKES, 1991), as the soft palate is both reported to prevent them actively (HERDT, 1997) and passively (EVANS, 1993). Furthermore, it is likely that the active movements of the soft palate are greatly diminished, if not suppressed, as most of its muscles are removed during the procedure. However, in this study, no episode of pharyngonasal regurgitation was observed nor reported. It is possible that, in brachycephalic dogs, after marked shortening of the soft palate, its obliterative role is passively carried out by the base of the tongue, pushed dorsally during the swallow reflex (HERDT, 1997) (especially as many of these dogs are macroglossic) and the redundant pharyngeal mucosal soft tissues. Palatine muscles are also reported to shorten the soft palate and to curl its caudal border downwards (HERMANSON, 1993), which eases the air flow through the widened pharynx during breathing. It is possible that the shortening of the soft palate and the rostral position of the suture line, which is thought to widen the pharynx by pulling the caudal border of the soft palate rostrally and ventrally, achieves the same effect.

No intraoperative complications were encountered, though the FFP appears subjectively more technically challenging and longer to perform than conventional techniques. The use of electrocautery is thought to ease the procedure. However, many authors recommend avoiding its use for soft palate surgery (HARVEY and VENKER-VON HAAGAN, 1975; BRIGHT and WHEATON, 1983), because it is expected to cause more postoperative oedema than scalpel or scissors, and that such oedema in the pharyngeal area could result in life-threatening airway obstruction. However, use of steroidal anti-inflammatory drugs in the perioperative period minimizes this risk (HAR-

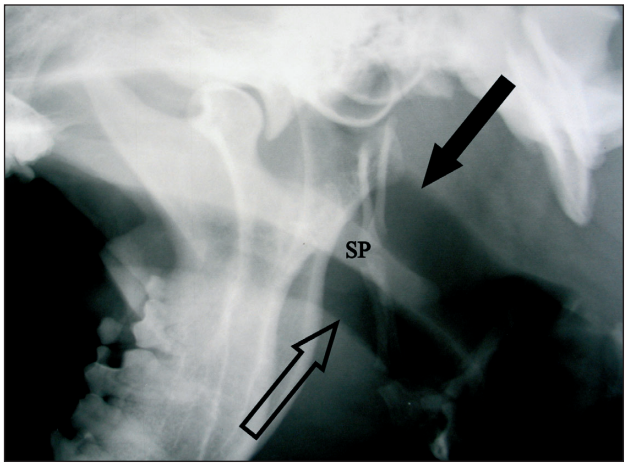


**Fig. 8:** Lateral radiographic appearance of the pharyngeal region of a mesocephalic dog; note as both the nasopharynx (black arrow) and oropharynx (hollow arrow) are unobstructed by the soft palate (SP).

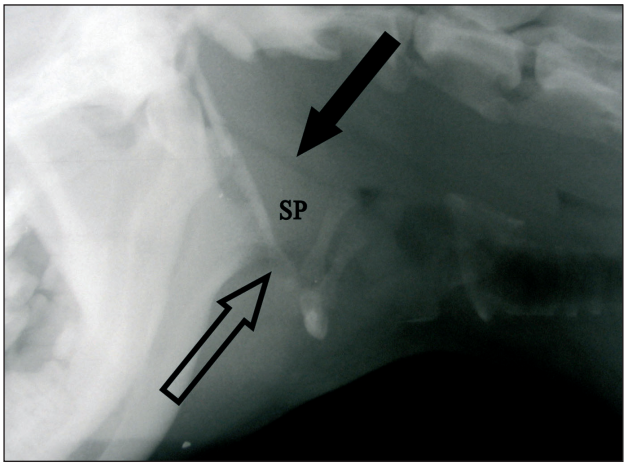


**Fig. 9:** Lateral radiographic appearance of the pharyngeal region of a brachycephalic dog; note as both the nasopharynx (black arrow) and oropharynx (hollow arrow) are reduced to a thin line of aeric density, as they are nearly completely obstructed by the excessively thick soft palate (SP).

**Fig. 10:** Excised portion of the soft palate after FFP

VEY, 1982b; DAVIDSON et al., 2001). Besides, with the FFP, the surgical site is displaced rostrally and the possible postoperative oedema or bleeding is likely to be located rostrally in the mouth, away from the pharynx. Furthermore, it is likely that such an oedema would be clinically less significant standing in a greatly thinned soft palate. The FFP is then believed to be less susceptible to the consequences of a possible oedema than conventional techniques, and electrocautery was therefore used here in all cases.

Some authors recommend performing a temporary tracheostomy before surgery to prevent postoperative airway obstruction caused by pharyngeal oedema (HENDRICKS, 1992; ORSHER, 1993) or to decrease encumbrance of the pharyngeal area during surgery (HARVEY and VENKER-VON HAAGAN, 1975). With the FFP, the surgical site is displaced rostrally, rendering the issue of intraoperative encumbrance of the pharynx and the risk for postoperative pharyngeal oedema of lesser importance. A temporary tracheostomy was therefore performed in only 6 dogs (10.9 %), always postoperatively when considered required because of possible life-threatening complications. In accordance with some authors (HARVEY and VENKER-VON HAAGAN, 1975), we performed temporary tracheostomies as soon as we first considered it might have been necessary, as it is a low-risk procedure (HARVEY and O'BRIEN, 1982). This might have made their incidence appear higher than considered necessary by some other surgeons. Despite this fact, our incidence compared similarly with previous reports of 5 to 27.9 % (HARVEY, 1982b; HARVEY and O'BRIEN, 1982; PONCET et al., 2006; TORREZ and HUNT, 2006).

Males were significantly more likely to be affected in our study ($p<0.001$). This differs from a study on BAS conducted in Australia in which no sex predisposition is reported (TORREZ and HUNT, 2006), but confirms the observation from a previous series of our centre, where 43 out of 61 dogs (78.7 %) were males (PONCET et al., 2006).

The perioperative mortality in our study (3.6 %) compares with perioperative mortalities of 0 to 14.8 % previously reported (HARVEY, 1982b; LORINSON et al., 1997; PONCET et al., 2006; TORREZ and HUNT, 2006), particularly as one death remained unexplained and may not be related to surgery.

All but one dog (97.5 %) showed improvement of their respiratory function after surgery. One dog was considered not to have shown any improvement, but its preoperative clinical signs were limited to constant snoring without any inspiratory efforts, stress or heat intolerance, or syncope. This dog carried on snoring but did not show any other respiratory difficulty.

As in the other clinical studies on this topic (HARVEY,

**Tab. 1:** Grading of respiratory clinical signs according to PONCET et al. (2005)

| Nature of respiratory signs | Never | Occasionally (<once monthly) | Regularly (Once weekly) | Daily (once daily) | Often (>once daily) | Constantly |
|---|---|---|---|---|---|---|
| Snoring | | | | | | |
| Inspiratory efforts | | | | | | |
| Stress or exercise intolerance | | | | | | |
| Syncope | | | | | | |

Grade 1 Grade 2 Grade 3

**Tab. 2:** Questionnaire for the owners' interview at follow-up

**BEFORE SURGERY**

1. Please quantify the frequency of the following respiratory clinical signs before surgery:

| Clinical signs | FREQUENCY | | | | | |
|---|---|---|---|---|---|---|
| | **Never** | **Occasionally** (less than once monthly) | **Regularly** (about once weekly) | **Daily** (about once daily) | **Often** (several times daily) | **Constantly** |
| ➢ **Snoring** | | | | | | |
| ➢ **Inspiratory difficulties** | | | | | | |
| ➢ **Short breathing** | | | | | | |
| ➢ **Exercise or stress intolerance** | | | | | | |
| ➢ **Dizziness, syncope** | | | | | | |
| **Other (specify):** | | | | | | |

**AFTER SURGERY**

2. After surgical treatment, have you observed an improvement of respiratory clinical signs?
   - ❑ Yes
   - ❑ No

3. If yes, this improvement has occured:
   - ❑ Immediately after surgery
   - ❑ Within 15 days after surgery
   - ❑ Within 6 weeks after surgery
   - ❑ Within 6 months after surgery
   - ❑ More than 6 months after surgery

4. Please quantify the frequency of the following respiratory clinical signs after surgery:

| Clinical signs | FREQUENCY | | | | | |
|---|---|---|---|---|---|---|
| | **Never** | **Occasionally** (less than once monthly) | **Regularly** (about once weekly) | **Daily** (about once daily) | **Often** (several times daily) | **Constantly** |
| ➢ **Snoring** | | | | | | |
| ➢ **Inspiratory difficulties** | | | | | | |
| ➢ **Short breathing** | | | | | | |
| ➢ **Exercise or stress intolerance** | | | | | | |
| ➢ **Dizziness, syncope** | | | | | | |
| **Other (specify):** | | | | | | |

**TODAY**

5. Is your dog currently on medication?
   - ❑ Yes
   - ❑ No

6. Please quantify the frequency of the following respiratory clinical signs today:

| Clinical signs | FREQUENCY | | | | | |
|---|---|---|---|---|---|---|
| | **Never** | **Occasionally** (less than once monthly) | **Regularly** (about once weekly) | **Daily** (about once daily) | **Often** (several times daily) | **Constantly** |
| ➢ **Snoring** | | | | | | |
| ➢ **Inspiratory difficulties** | | | | | | |
| ➢ **Short breathing** | | | | | | |
| ➢ **Exercise or stress intolerance** | | | | | | |
| ➢ **Dizziness, syncope** | | | | | | |
| **Other (specify):** | | | | | | |

1982a,b; LORINSON et al., 1997; PONCET et al., 2006; TORREZ and HUNT, 2006), the concomitancy of another procedure addressing another component of BAS (here: rhinoplasty) renders impossible to distinguish between the respective participation of each procedure in this improvement. Furthermore, the sole clinical appreciation would probably be insufficient in evaluating the efficacy of each procedure, and dynamic measurements would certainly be required. Because most dogs diagnosed with BAS suffer from several of its components, it seems hardly feasible to design a clinical study in which correction of each of its components is separate and dynamic measurements are performed.

Improvement was rapidly observed (immediately in 61.5 % of cases, within 15 days in 87.1 % of cases), and was durable since at a mean follow-up of 379 days, 82.5 % of dogs had improved their respiratory score by at least 1 point. Notably, some dogs were considered to be improved by their owners but stayed in the same grading category, often because of persistent snoring despite improvement of other respiratory clinical signs. On the other hand, our results support the well spread conception that, although surgically treated and markedly improved, these dogs can rarely be considered normal as for their respiratory function: 35 % and 10 % of dogs were still graded 2 and 3, respectively, for respiratory signs at time of follow-up.

During the study period, the FFP was used exclusively for treatment of elongated soft palate, and has shown to be safe and efficient regardless of the soft palate thickness. It can therefore be used for any ESP and will be most valuable if the soft palate appears, either pre or intraoperatively, to be excessively thick.

**Acknowledgements**

The authors would like to thank Prof. Robert N. White and Alexander Tichy for their most valuable help in reviewing our manuscript and with statistics, respectively, as well as Drs. Cyrill Poncet and Valérie Freiche for their active involvement in the clinical aspects of this study.

## References

AMIS, T. C., KURPERSHOEK, C. (1986): Pattern of breathing in brachycephalic dogs. Am. J. Vet. Res. **47**, 2200-2204.

BRIGHT, R. M., WHEATON, L. G. (1983): A modified surgical technique for elongated soft palate in dogs. J. Am. Anim. Hosp. Assoc. **19**, 288.

CLARK, G. N., SINIBALDI, K. R. (1994): Use of a carbon dioxide laser for treatment of elongated soft palate in dogs. J. Am. Vet. Med. Assoc. **204**, 1779-1781.

DAVIDSON, E. B., DAVIS, M. S., CAMPBELL, G. A., WILLIAMSON, K. K., PAYTON, M. E., HEALEY, T. S., BARTELS, K. E. (2001): Evaluation of carbon dioxide laser and conventional incisional techniques for resection of soft palates in brachycephalic dogs. J. Am. Vet. Med. Assoc. **219**, 776-781.

DUPRÉ, G., FINDJI, L. (2004): La palatoplastie modifiée chez le chien. Le Nouveau Praticien Vétérinaire. **20**, 553-556.

DUPRÉ, G., FINDJI, L., PONCET, C. M. (2005): The folded flap palatoplasty: a new technique for treatment of elongated soft palate in dogs. 2005 ECVS annual meeting Lyon, France, p. 265-267.

EVANS, H. (1993): The digestive apparatus and abdomen. In: EVANS, H. (ed.): Miller's anatomy of the dog. 3rd ed., Saunders, Philadelphia, p. 385-462.

HARVEY, C. E. (1982a): Upper airway obstruction surgery. 8: Overview of results. J. Am. Anim. Hosp. Assoc. **18**, 567-569.

HARVEY, C. E. (1982b): Upper airway obstruction surgery. 2: Soft palate resection in brachycephalic dogs. J. Am. Anim. Hosp. Assoc. **18**, 538-544.

HARVEY, C. E., O'BRIEN, J. A. (1982): Upper airway obstruction surgery. 7: Tracheotomy in the dog and cat: analysis of 89 episodes in 79 animals. J. Am. Anim. Hosp. Assoc. **18**, 563-566.

HARVEY, C. E., VENKER-VON HAAGAN, A. (1975): Surgical management of pharyngeal and laryngeal airway obstruction in the dog. Vet. Clin. North Am. **5**, 515-535.

HENDRICKS, J. C. (1992): Brachycephalic airway syndrome. Vet. Clin. North Am. Small Anim. Pract. **22**, 1145-1153.

HENDRICKS, J. C., KLINE, L. R., KOVALSKI, R. J., O'BRIEN, J. A., MORRISON, A. R., PACK, A. I. (1987): The English bulldog: a natural model of sleep-disordered breathing. J. Appl. Physiol. **63**, 1344-1350.

HERDT, T. (1997): Movements of the gastrointestinal tract. In: CUNNINGHAM, J. (ed.): Textbook of veterinary physiology. 2nd ed., Saunders, Philadelphia, p. 272-289.

HERMANSON, J. E. (1993): The muscular system. In: EVANS, H. (ed.): Miller's anatomy of the dog. 3rd ed., Saunders, Philadelphia, p. 258-384.

LORINSON, D., BRIGHT, R. M., WHITE, R. A. S. (1997): Brachycephalic airway obstruction syndrome - a review of 118 cases. Canine Pract. **22**, 18-21.

MONNET, E. (2003): Brachycephalic airway syndrome. In: SLATTER, D. (ed.): Textbook of small animal surgery. 3rd ed., Saunders, Philadelphia, p. 808-813.

ORSHER, R. (1993): Brachycephalic airway disease. In: BOJRAB, M. (ed.): Disease mechanisms in small animal surgery. Lea & Febiger, Philadelphia, p. 369-370.

PONCET, C. M., DUPRE, G. P., FREICHE, V. G., BOUVY, B. M. (2006): Long-term results of upper respiratory syndrome surgery and gastrointestinal tract medical treatment in 51 brachycephalic dogs. J. Small Anim. Pract. **47**, 137-142.

PONCET, C. M., DUPRE, G. P., FREICHE, V. G., ESTRADA, M. M., POUBANNE, Y. A., BOUVY, B. M. (2005): Prevalence of gastrointestinal tract lesions in 73 brachycephalic dogs with upper respiratory syndrome. J. Small Anim. Pract. **46**, 273-279.

TORREZ, C. V., HUNT, G. B. (2006): Results of surgical correction of abnormalities associated with brachycephalic airway obstruction syndrome in dogs in Australia. J. Small Anim. Pract. **47**, 150-154.

WYKES, P. M. (1991): Brachycephalic airway obstructive syndrome. Probl. Vet. Med. **3**, 188-197.

**Authors' address:**

Dr. Laurent Findji, current address: Veterinary Referrals Cancer and Critical Care, 1 West Mayne, Bramston Way, Southfields, Laindon, Essex SS15 6TP, U.K.; Dr. Gilles Dupré, current address: Klinik für Chirurgie und Augenheilkunde, Veterinärmedizinische Universität Wien, Veterinärplatz 1, A-1210 Wien.

e-mail: laurent.findji@gmail.com